

Postoperative care

EDITORIAL

Improving cataract outcomes through good postoperative care

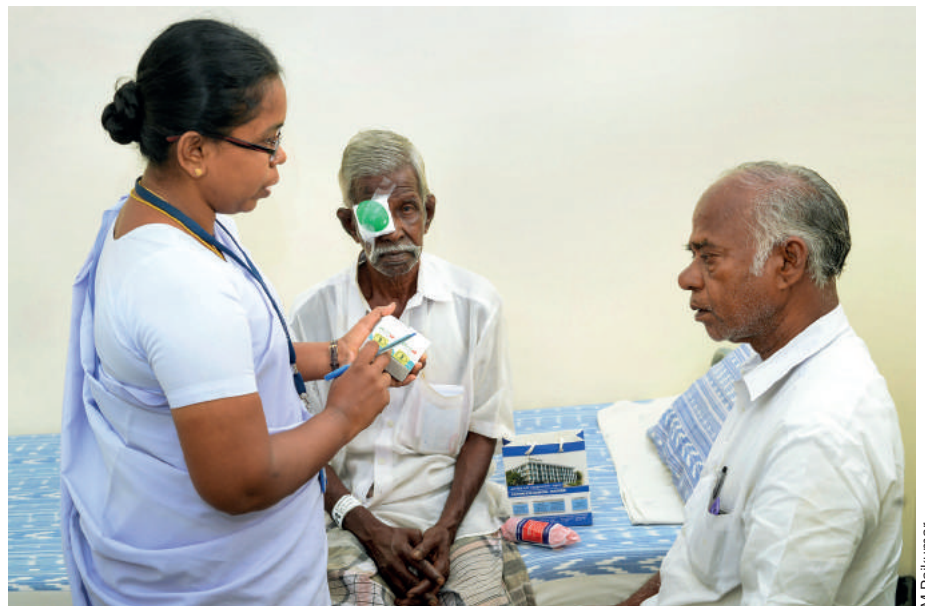

Nick Astbury

Clinical Senior Lecturer: International Centre for Eye Health, London School of Hygiene and Tropical Medicine, London, UK.

Cataract surgery is one of the most successful and frequently performed operations worldwide, and yet cataract remains the commonest cause of global blindness.¹ This is in part due to the shortage and uneven distribution of trained personnel in some countries. More worryingly, a high rate of cataract blindness also reflects poor visual outcomes after surgery, as has been documented in many RAAB (rapid assessment of avoidable blindness) studies.² In turn, poor visual acuity outcomes can be the result of inadequate pre-operative assessment (such as inaccurate biometry and/or a failure to detect signs which indicate that surgery may be complicated), complications during the surgical procedure itself, and poor postoperative management (including a lack of refraction).

Postoperative care does not always receive the attention it deserves. For example, when looking for information



M Rajkumar

A nurse explains how to apply postoperative medication. INDIA

online, there are six times as many search results available about cataract surgery as there are about postoperative care – despite the latter being a vital component in achieving a good visual outcome.

In this issue of the *Community Eye Health Journal*, Dr George Ohito from St Mary's Mission Hospital, Langata, Kenya, describes postoperative care as "an integral part of cataract management, with the objectives of minimising patient discomfort and pain, preventing injury and complications, and improving surgical and vision outcomes" (page 26). This definition covers all aspects: counselling, advice following surgery, and – importantly – postoperative refraction. The latter is important as there is often residual refractive error after cataract surgery, whether from astigmatism or inaccurate biometry.

The VISION 2020 initiative³ requires three components – trained personnel,

equipment and facilities, and community participation. Good postoperative care starts even before surgery and involves patients and the community by means of counselling to allay fears and manage expectations (see the article on page 23). Patients may not access eye care services because they fear surgery or worry that they won't be able to work after an operation. Patients and their carers need reassurance and advice and must know what to do when they return home. If this is done well, and the outcomes are good, others in the community will have confidence in the eye team and be more likely to present themselves for surgery when their time comes.

Although the surgical team's responsibility doesn't stop when the patient leaves the operating theatre, patients also have a role to play.

Continues overleaf ►

ABOUT THIS ISSUE



Elmien Wolvaardt Ellison

Editor: *Community Eye Health Journal*, International Centre for Eye Health, London, UK.

Responsibility for our patients does not end when they leave the operating theatre – ensuring good eye health and visual outcomes in the long term also requires good postoperative care, counselling and follow-up. This issue offers practical advice and emphasises the importance of involving patients and family members in postoperative care.

In this issue

- 21 **Improving cataract outcomes through good postoperative care**
- 23 **Working with patients to optimise cataract outcomes**
- 24 **Routine postoperative nursing management**
- 25 **Postoperative cataract care – the Aravind perspective**
- 27 **Detecting and managing complications in cataract patients**
- 29 **The basics of good postoperative care after glaucoma surgery**
- 32 **Postoperative care for paediatric cataract patients**
- 34 **Paediatric cataract: challenges and complications**
- 36 **CLINICAL SKILLS**
Cleaning and dressing the eye after surgery
- 37 **EQUIPMENT AND MAINTENANCE**
Understanding and caring for a lensmeter
- 38 **TRACHOMA UPDATE**
- 39 **CPD QUIZ**
- 40 **NEWS AND NOTICES**

EDITORIAL *Continued*

On page 25, authors Aravind, Baam and Ravindran suggest that there should be a 50:50 partnership between the patient and the eye care team so that both parties contribute to a successful visual outcome. Patients must know how to look after their operated eye and be empowered to take immediate action if they notice any symptoms or signs that might indicate a complication. This is why good counselling – before patients leave the hospital – is so important.

In this edition, we cover many aspects of postoperative care, tailored for different settings. Patients may be treated as day cases or may be in-patients who live far from the hospital. The timing of postoperative refraction will vary, but the important point is that it is done. Patients also have different home circumstances, and the postoperative advice given to them must be adjusted accordingly.

To achieve a good outcome from cataract surgery, a team effort is needed – community eye care workers, nurses, counsellors, eye surgeons and optometrists, as well as the patients and their carers – all have to have an understanding of the cataract journey (from first diagnosis to discharge), the complications that may arise, and

how they can be prevented or their impact minimised.

For postoperative care to be **consistently** successful, systems need to be in place to support the eye team in this important work. This can include having a checklist to ensure that every

‘To achieve a good outcome from cataract surgery, a team effort is needed’

patient has been given the care and information they need before leaving the hospital, having written information ready to hand out to patients, and undertaking regular monitoring. A culture of honesty and learning from mistakes – rather than denial and blame – should also be encouraged. A beautifully completed cataract operation should only be counted a success when the patient is back home, enjoying seeing again, with appropriate correction of any refractive error.

To use a sporting analogy, the end of the operation signals half-time, but the game can still be lost if attention is not paid to the postoperative period and refraction (the second half). The game is won by a joint team approach and not just by one star player – and remember that the patient is a member of that team!

References

- 1 <http://www.who.int/blindness/causes/en/>
- 2 <http://iceh.lshtm.ac.uk/rapid-assessment-of-avoidable-blindness/>
- 3 <http://www.iapb.org/vision-2020>



“Improving eye health through the delivery of practical high-quality information for the eye care team”

Volume 29 | ISSUE 94

Supporting VISION 2020:
The Right to Sight



Editor

Elmien Wolvaardt
editor@cehjournal.org

Editorial committee

Allen Foster
Clare Gilbert
Nick Astbury
Daksha Patel
Richard Wormald
Matthew Burton
Hannah Kuper
Priya Morjaria
G V Murthy
Fatima Kyari
David Yorston
Sally Crook
Serge Resnikoff
Babar Qureshi
Janet Marsden
Noela Prasad

Regional consultants

Hugh Taylor (WPR)
Leshan Tan (WPR)
GVS Murthy (SEAR)
R Thulsiraj (SEAR)
Babar Qureshi (EMR)
Mansur Rabi (EMR)
Hannah Faal (AFR)
Kovin Naidoo (AFR)
Winjiku Mathenge (AFR)
Ian Murdoch (EUR)
Janos Nemeth (EUR)
Van Lansingh (AMR)
Andrea Zin (AMR)

Editorial assistant Anita Shah

Design Lance Bellers

Printing Newman Thomson

CEHJ online

Visit the *Community Eye Health Journal* online. All back issues are available as HTML and PDF. Visit: www.cehjournal.org

Online edition and newsletter

Sally Parsley: web@cehjournal.org

Consulting editor for Issue 94

Nick Astbury

Please support us

We rely on donations/subscriptions from charities and generous individuals to carry out our work.

We need your help.

Subscriptions in high-income countries cost UK £100 per annum.

Contact Anita Shah admin@cehjournal.org or visit our website: www.cehjournal.org/donate

Subscriptions

Readers in low- and middle-income countries receive the journal **free of charge**. Send your name, occupation, and postal address to the address opposite. French, Spanish, and Chinese editions are available. To subscribe online, visit www.cehjournal.org/subscribe

Address for subscriptions

Anita Shah, International Centre for Eye Health, London School of Hygiene and Tropical Medicine, Keppel Street, London WC1E 7HT, UK.
Tel +44 (0)207 958 8336
Email admin@cehjournal.org

Correspondence articles

We accept submissions of 800 words about readers' experiences. Contact: Anita Shah: correspondence@cehjournal.org

Published by the International Centre for Eye Health, London School of Hygiene & Tropical Medicine

Unless otherwise stated, authors share copyright for articles with the Community Eye Health Journal. Illustrators and photographers retain copyright for images published in the journal.

Unless otherwise stated, journal content is licensed under a Creative Commons Attribution-NonCommercial (CC BY-NC) license which permits unrestricted use, distribution, and reproduction in any medium for non-commercial purposes, provided that the copyright holders are acknowledged.

Woodcut-style graphics by Victoria Francis and Teresa Dodgson.

ISSN 0953-6833

Disclaimer

Signed articles are the responsibility of the named authors alone and do not necessarily reflect the views of the London School of Hygiene & Tropical Medicine (the School). Although every effort is made to ensure accuracy, the School does not warrant that the information contained in this publication is complete and correct and shall not be liable for any damages incurred as a result of its use.

The mention of specific companies or of certain manufacturers' products does not imply that they are endorsed or recommended by the School in preference to others of a similar nature that are not mentioned. The School does not endorse or recommend products or services for which you may view advertisements in this Journal.



Working with patients to optimise cataract outcomes



Nick Astbury
Clinical Senior Lecturer: International Centre for Eye Health, London School of Hygiene and Tropical Medicine, London, UK.



Ebbly Adekhera
Nursing Officer: Sabatia Eye Hospital, Wodanga, Kenya.



Lily A Nyamai
Tutorial Fellow: Department of Ophthalmology, University of Nairobi, Nairobi, Kenya. lilnyamai@gmail.com

One of the delights of ophthalmology is to witness the joy on the face of a patient with cataract when the dressing is taken off and sight has been restored. Unfortunately, for some patients, the result does not live up to their expectations. Despite cataract surgery being one of the most successful surgical interventions available, there is evidence that the visual outcome of cataract surgery in sub-Saharan Africa is not always good (defined as a VA of 6/18 or better). The proportion of good outcomes range from only 23% up to 70%, failing to reach the WHO target of 85% or better.¹

A good outcome is crucial for the individual patient, but will also have a wider impact on the community. In sub-Saharan Africa, for example, uneasiness about surgery can mean that patients stay away – more so if they hear about an operation that was not successful. Good outcomes in cataract surgery, in those brave enough to undergo the procedure, are therefore essential to encourage other people with poor vision from the community to come forward for examination and treatment.

In order to optimise good outcomes, patients need to have relevant information. They must have confidence in the eye service and in the people providing it, so that they will be willing to attend follow-up visits and to come back immediately if they notice anything wrong after the operation.

It is helpful to have a team member who speaks the language of patients as this can help to increase people's understanding of any information being shared and boost their trust in the eye service.

Before surgery

Patients and their families must be given advice and counselling about the operation, including what happens before, during and after. They should then sign an informed consent form. It is our responsibility to ensure that



Lindsay Hampton

A woman tells new patients about her cataract operation. KENYA

the patient understands – in straightforward terms – what is going to happen and what this means for them and their eye health. We must also take time to address any fears, doubts and myths about cataract surgery.

It is important to ensure that patients and their families have realistic expectations about their vision after surgery. They must understand the risks and benefits, including the potential effect of different complications on their eyesight. A disappointed patient is not a good advertisement for our service.

Our patients also have a role to play in alerting the eye team to potential complications at an early stage. Before surgery, explain to patients how their eyes will look and feel after a successful operation, including what level of discomfort is normal at the different stages of recovery. Encourage them to speak with an eye team member if they experience anything that concerns them.

After surgery

After the operation, patients should be given clear instructions about how to look after their operated eye when they are back at home (see panel on page 24). Give specific information about follow-up visits (where to go, when, and at what time) and ensure patients know how to get in touch with the eye clinic or their surgeon if they have any signs or symptoms that can indicate a complication (worsening sight, increasing pain,

redness, swelling or discharge).

Discussion groups for patients, based on their gender and initial visual outcome, offer an opportunity to talk about coping with the challenges of self-care and follow-up appointments, which may be different for each individual. Giving patients an opportunity to attend such groups may help to allay fears and can give them an opportunity to ask questions if they are uncertain about anything.

Discharge

Before discharging a patient, check that they have all of the following:

- Instruction sheet to take home
- Clinic contact details
- Eye shield (if available)
- Eye drops and instructions for storage and use
- Painkillers to use at home
- A follow-up appointment date and time.

Follow-up

We recommend that cataract patients are followed up and examined as follows:

- **The day after surgery (day 1)**, in the hospital.
- **4–8 weeks after surgery.** This visit is important, as it is also the time to conduct postoperative refraction. Actively encourage patients to attend, for example by including the visit in the price of the cataract operation.

Transport may be a barrier for some

Continues overleaf ➤

patients and it may be helpful to conduct follow-up appointments in primary health care centres in the community.

Postoperative refraction

Postoperative refraction and provision of spectacles (if needed) are essential to ensure the best possible visual outcome for a patient. This is important because satisfied patients will encourage others in the community to undergo cataract surgery.

During the 4–8-week follow-up appointment, refract both eyes and accurately check the visual acuity. Make sure you understand the patient's refractive needs (e.g. their ideal working distance).

If there is no intraocular lens, carefully check the back vertex distance and centring of the spectacles.

Reference

- 1 Blindness and visual impairment due to age-related cataract in sub-Saharan Africa: a systematic review of recent population-based studies. Andrew Bastawrous, William H Dean and Justin C Sherwin. *Br J Ophthalmol* 2013 97: 1237-1243. Originally published online in May 21, 2013.

Instructions for patients

Even though you may feel well after surgery, you have had a big operation. You should take care of yourself and allow your eye to heal properly.

Dos

- Clean eyelids morning and evening with a moist, *clean* face cloth, avoiding pressure on the eyeball.
- If possible, protect the operated eye for the first week by wearing an eye shield when sleeping and sunglasses or prescription spectacles during the day.
- Instil eye drops as prescribed.
- Follow a normal diet after surgery with enough water and fibre/roughage (from fruit, vegetables and whole grains) to avoid constipation.
- Resume your regular medications, including any prescribed eye drops, immediately.

- **Contact the eye clinic in case of worsening sight, increasing pain, redness, swelling or discharge.**

- Keep your follow-up appointments without fail.
- You can wash your hair a day after surgery but avoid soap, water or shampoo entering the eye.
- You may resume sexual activity once you feel comfortable.

Don'ts

- Don't wear eye makeup for at least a week, and don't use shop-bought cotton wool balls on your eyelids. These may leave behind particles of cotton, which may attract germs, leading to infection.
- Avoid sleeping on the operated side.
- Do not lift heavy weights above 5 kg for 2 weeks.
- Avoid swimming for 2 weeks.

Routine postoperative nursing management



Ebby Adekhera

Nursing officer: Sabatia Eye Hospital, Wodanga, Kenya.

The nursing process is a systematic, scientific approach to managing a range of patients. This article explains how the nursing process can be applied when caring for cataract patients who have been admitted.

The nursing process consists of five phases of management:

- Assessment
- Diagnosis
- Planning
- Implementation
- Evaluation.

Assessment

Assessment is done by using effective communication and observational skills to carry out a complete and holistic nursing assessment of every patient's needs. An actual or potential problem with the patient (i.e. pain, or an infection following cataract surgery) may be discovered.

Before surgery, take a history of the patient and obtain their baseline blood pressure and pulse (Figure 1).

After surgery, look at the patient's facial expression to determine if she or he is in pain and ask the patient how she or he is feeling. Measure vital signs (pulse and blood pressure).

From the first day after surgery (day 1), carry out an eye examination to look at

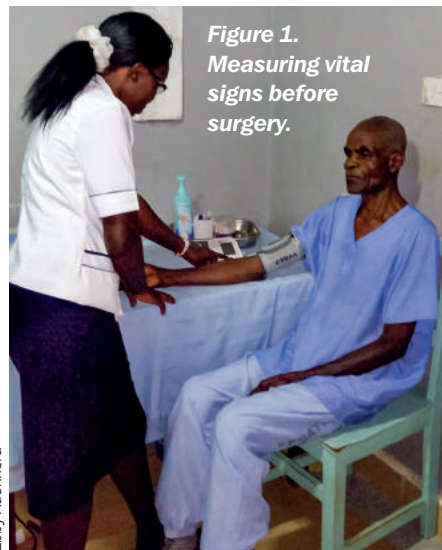

Figure 1. Measuring vital signs before surgery.

Ebby Adekhera

visual acuity, the state of the wound, the conjunctiva, the cornea, the anterior chamber, the pupil and the position of the intraocular lens. Observe the patient for any signs of infection (redness, swelling or discharge), ask about pain and treat or refer the patient as appropriate.

At later follow-up visits, measure visual acuity to assess the need for refraction and spectacle correction, in collaboration with the patient.

Diagnosis

After the assessment phase, determine and prioritise the patient's nursing needs, **from their basic health needs to their eye care.** Most importantly, be on the lookout for signs of complications: most

commonly worsening sight, increasing pain, redness, swelling or discharge.

Planning

With the patient's agreement, consider each of the problems identified, plan to manage them according to priority and set a measurable goal. For example, for pain, plan to give analgesics and reassure the patient. If there are signs of a postoperative complication, plan to either treat the complication or make a referral, depending on the suspected complication.

Implementation

Next, record the methods by which the goals will be achieved in a clear format that all can understand. For example, record the time and dose when analgesics are administered. It is important to know the appropriate dose and be able to identify any side effects.

Evaluation

This is a continuous process in which we look at the initial and the present situation, compare the two and evaluate progress towards the goals identified in the previous stages. If progress towards the goal is slow or if regression has occurred, change the plan of care accordingly. If the goal has been achieved, then the care can cease. For example, if a patient is relieved of pain, stop the analgesics. If not, adjust the plan and change to another form of management, depending on the cause of the pain.



Postoperative cataract care: the Aravind perspective



Aravind Haripriya
Chief: Cataract services,
Aravind Eye Hospital, Madurai, India.



Zervin R Baam
Fellow: Cataract Services,
Aravind Eye Hospital, Madurai, India.



RD Ravindran
Chairman: Aravind Eye Care System,
Madurai, India.

“Your operation has been a success.”

It is such a relief for a patient to hear these words from the operating ophthalmologist. All is well that ends well. However, it is essential for us as eye care professionals to make the patient aware that the end of a successful cataract operation is not the end of her or his treatment for cataract. Good postoperative care is as important as the care taken by the surgeon before and during surgery. At Aravind Eye Hospitals, we make a point of stressing good postoperative care, especially since excellent surgery can have a poor outcome if the postoperative care is not adequate.

At Aravind many of our patients are operated on as day cases and others are admitted, particularly patients identified with cataract during outreach activities. For all cataract operations the procedure ends with the administration of intracameral antibiotics (for endophthalmitis prophylaxis). We use intracameral moxifloxacin for this, which has reduced postoperative endophthalmitis from 8 per 10,000 operations to 2 per 10,000.¹ Following this, a drop of 5% povidone

iodine is instilled into the conjunctival sac and the eye is patched.

Patients are taken to a recovery room, where they are counselled regarding care to be taken during the postoperative period. The correct method of instilling drops is shown to them during counselling. Patients are instructed to clean the lid margins and adjoining area with surgical cotton (given to them in their postoperative medicine kit) and advised not let any fluid or foreign body enter the eye. Dark glasses (sunglasses) are recommended to be worn outdoors for protection and to reduce glare.

Day surgery patients are sent home wearing an eye patch and eye shield and instructed to do the following on the day of surgery:

- Remove the eye patch and eye shield 2–3 hours after reaching home.
- A total of 6 hours after surgery, instil antibiotic drops every hour (5 to 6 times in total) and topical steroid drops every two hours (3 times in total). From the next day, the steroids are increased to 6 times a day and then slowly tapered.
- Wear the sterile eye patch (given to patients on discharge) on the first night after surgery.

For inpatients, the same regime is followed except that the eye drops are administered by nurses.

Alongside the use of intracameral

antibiotics and topical povidone iodine at the time of surgery, topical antibiotic drops in the immediate postoperative period help to prevent infection caused by contamination of the anterior chamber during surgery or in the immediate postoperative period.

If the posterior capsule has been ruptured during surgery, patients are

started on a course of systemic antibiotics (ofloxacin 200 mg twice daily) on the day of surgery for a period of 3 days, as additional prophylaxis against endophthalmitis.

All patients are examined on the first day after surgery in order to rule out any early postoperative

complications, to diagnose any fundus pathology which was not possible pre-operatively due to media haze, and to assess the immediate postoperative visual outcome.

Examination includes measurement of visual acuity with and without a pinhole, slit lamp examination and fundus examination. The patients' pupils are dilated prior to examination. Particular attention is paid to the cataract wound (to check whether the wound has opposed well), the clarity of the cornea, the anterior chamber depth, cellular reaction and the location and centration of the intraocular lens. A second operation is planned if there is wound leak, significant retained lens matter or a decentred intraocular lens (IOL). Fundus examination is undertaken using a +90D lens to rule out glaucoma or retinal pathology.

In the event of posterior capsular rupture (PCR), more detailed examination is required. The presence of vitreous in the anterior chamber is checked, to see whether it is touching the cornea (causing pupillary block) or whether strands of vitreous are incorporated into the wound. In the case of the latter, Nd:YAG vitreolysis is planned, as well as surgical anterior vitrectomy in case of vitreous in the anterior chamber. In the event of a PCR, detailed examination of the vitreous cavity is also required to rule out dislocated nuclear or cortical material.

On the first postoperative day (day 1), patients are counselled again; the need for follow up after 30 days is emphasised and the postoperative medication regimen is

Continues overleaf ➤

‘Good postoperative care is as important as the care taken by the surgeon before and during surgery’

M Rajkumar



A patient counsellor explains cataract surgery and the various types of implants (intraocular lenses [IOL]) to the patient and relatives. INDIA


explained. Patients are also advised to see an ophthalmologist immediately if they have sudden pain, redness or decreased vision.

At Aravind, great importance is given to counselling: specially-trained counsellors are given the job of adequately advising patients and answering any questions they may have. At the end of counselling, a checklist is used to ensure all relevant aspects are communicated to the patient (Figure 1). Patients are also told when they can resume various activities.

Most patients who were admitted are discharged on the first postoperative day; however those coming as a result of our outreach activities are discharged on the second or third day depending on the distance to their village. A detailed discharge summary is given which includes the details of the postoperative medications, i.e. topical steroid and antibiotic eye drops.

Steroids are used 6 times per day for the first week and tapered each week over 6 weeks. Topical antibiotics are used 3 times daily for 2 weeks postoperatively. Topical non-steroidal anti-inflammatory drugs (NSAIDs), such as nepafenac or ketorolac, are generally started routinely at the 1 month follow-up visit to reduce

Figure 1. A counselling checklist helps to ensure good communication with the patient

Post-Operative Counselling Checklist - Cataract Surgery	
Name : _____	Age : _____ Gender : M / F
M.R.No : _____	Date: _____
<input type="checkbox"/> Surgical procedure explained <input type="checkbox"/> Certificates handed over (Mediclaim, Leave) <input type="checkbox"/> Eye cleaning method	
Instructions about the medication	
<input type="checkbox"/> Method of opening the bottle without touching the nozzle <input type="checkbox"/> Two drops of each medication <input type="checkbox"/> Explained daily medication schedule <input type="checkbox"/> Explained interval between medications <input type="checkbox"/> If medications gets over before follow - up, buy new one	
Follow - up	
<input type="checkbox"/> Ask if patient can come for follow-up, if not explain need for local eye exam. <input type="checkbox"/> Confirm convenience of follow-up date and explain importance <input type="checkbox"/> Explained how to change the follow-up date if required <input type="checkbox"/> Explained importance of continuing medication in case of delayed follow-up. <input type="checkbox"/> Explained to consult an ophthalmologist immediately in case of pain / redness / defective vision.	
Counsellor Signature & Time _____	Patient / Attender Signature _____
 ARAVIND EYE HOSPITALS - FREE SECTION AEH/FH/IP/02	

the incidence of cystoid macular oedema (CME) and to prevent rebound inflammation, which may occur after the steroids are tapered and stopped. In high risk cases such as PCR with vitreous loss,

or if there was CME following surgery to the first eye, NSAID drops are started immediately after surgery.

At the first month follow-up visit, patients undergo refraction and spectacles are prescribed based on their needs. Their intraocular pressure is checked to rule out raised intraocular pressure following the use of topical steroids. The eye is examined comprehensively for any sequelae following surgery and the other eye is assessed in order to plan the timing of a cataract operation on the second eye, if needed. Some patients may be called back sooner than one month if there were any surgical or postoperative complications.

Patients are advised to undergo an annual follow-up examination after surgery in both eyes.

Whereas the surgeon and eye team have a greater role to play in the surgical care, postoperative care involves sharing responsibility between the eye team and the patient. It is crucial that the patient is educated regarding the importance of compliance with treatment and follow-up in order to ensure an excellent outcome.

Reference

1 Haripriya, Chang DF, Namburam S, Smita A, Ravindran RD. Efficacy of Intracameral Moxifloxacin Endophthalmitis Prophylaxis at Aravind Eye Hospital. *Ophthalmology*.2016 Feb;123(2):302-8.



FROM THE FIELD

Care after cataract surgery in Nairobi, Kenya

George S Odhiambo Ohito is a cataract surgeon at St Mary's Mission Hospital in Langata, Nairobi.

Postoperative care of the cataract patient is an integral part of cataract management with the objectives of minimising patient discomfort and pain, preventing injury and complications, and improving surgical and vision outcomes. It need not be so restrictive as to cause patients to have a significant lifestyle change.

Postoperative care is planned and discussed with the patient before surgery, and advice is adapted to fit the circumstances of each patient. For example, to insist that an old widow who lives alone in a rural area does not cook her food using a firewood stove, is to deny her meals for the recovery period. Her only option would be to 'break the

rules', which might in turn reduce her confidence in the advice and treatment regime she has been given, for example regarding the use of medication.

At St Mary's Mission Hospital in Nairobi, almost all operations are done as day cases and we have limited the postoperative visits to three, unless complications arise. Visits take place on day 1 (the first day after surgery), day 8 (or 1 week) and at 6-8 weeks (for a final examination and refraction). We have an autorefractor and aim to refract all patients at 6-8 weeks. In the event of any complications, the visits may be increased as necessary.

Immediately after surgery, we advise adult patients to take 1,000 mg of paracetamol, repeated every 8 hours for 1-2 days, as needed. The dressing is left on until the day after surgery and is only removed by the clinic staff. On the first day after surgery (day 1), we remove the dressing, clean the eye and check the eye

for complications. If there are none, we prescribe a combined steroid/antibiotic drop to reduce inflammation and as a prophylaxis against bacterial infection. (We avoid ointments as they can temporarily affect the vision.) We do not routinely prescribe cycloplegics unless there is significant fibrinoid reaction. After the first week, patients are given plain steroid eyedrops to use at home for 2-3 weeks.

We have simplified the postoperative instructions to patients as follows:

- No special diet, eat your normal meals.
- Have a bath, just avoid splashing water directly into the eye, and avoid soap on the face for two weeks.
- Watch TV if comfortable.
- Use dark glasses (sunglasses) if you can afford a pair.
- Avoid strenuous exercise or heavy work for at least a month.

Generally, we encourage an early return to normal life.



Detecting and managing complications in cataract patients

**Nick Astbury**

Clinical Senior Lecturer: International Centre for Eye Health, London School of Hygiene and Tropical Medicine, London, UK.

**Lily A Nyamai**

Tutorial Fellow: Department of Ophthalmology, University of Nairobi, Nairobi, Kenya. lilynyamai@gmail.com

In order to ensure good cataract outcomes with the minimum of complications, the following are all essential:

- Well-trained staff
- Excellent teamwork
- Good pre-operative evaluation (including history taking, examination, investigations and biometry)
- Infection control (including prophylaxis)
- Functioning equipment
- Sufficient consumables (including intraocular lenses)
- Good postoperative care.

Even if these are all in place, problems can arise with a patient who can't keep still in theatre, an eye that is deep-set and difficult to access, a small pupil, weak lens zonules (whether due to pseudo-exfoliation or subluxation) or a hyper-mature cataract that requires a high degree of surgical skill. If the posterior capsule is ruptured and there is vitreous loss, there is a higher risk of postoperative complications such as endophthalmitis, retinal detachment or macular oedema. Poor vision postoperatively can be caused by uncorrected refractive error, particularly if no intraocular lens (IOL) was used or the wrong power IOL was inserted.

Things can also go wrong in the postoperative period if postoperative complications are missed, or if perioperative complications are not managed well. It is therefore important that all eye health workers who come into contact with the patient postoperatively know the basics of what the operation entails and what is normal so that they are alert to any signs or symptoms that might require action. They must know how to recognise an early or late complication and how to manage it effectively to prevent loss of sight – which we will cover in more detail in this article.

Complications are rare and in most cases can be treated effectively. In a small proportion of cases, further surgery may be needed. Very rarely, some complications can result in blindness.



This patient has a hazy cornea and a peaked pupil following cataract surgery. There was also vitreous loss during surgery. KENYA

Some complications may arise despite a good initial surgical outcome but in most settings they can be avoided through effective communication between the eye team and the patients. Good rapport is needed with an honest discussion about expectations right from the start.

As a general rule, worsening sight, increasing pain, redness, swelling and discharge are all symptoms or signs that should trigger a referral.

What follows is a list of complications and advice on how to manage them in order to minimise the risk of a poor outcome.

Early complications

These are complications which occur immediately following the operation (and may have their origin in the operation itself). With adequate vigilance and monitoring of patients postoperatively they can be detected and treated while the patient is still in the clinic. In addition, ensure that patients know they must alert a member of staff if:

- they experience pain (rather than slight discomfort)
- if their vision is reduced in any way
- if they notice any redness, swelling or discharge in their eyes.

Discomfort. Most patients will stay overnight before having their first dressing the next day. Some mild irritation can be expected which usually settles down

over 1–2 days and the eyesight gradually improves. Severe pain is unusual and may indicate raised pressure in the eye or the start of an infection. If the eyesight is improving and the eye not unduly red and the discomfort is mild, simply reassure the patient that it will get better.

Bruising or swelling of the eyelids/ sub-conjunctival haemorrhage may occur if a sub-Tenon's or peri-bulbar local anaesthetic injection has been given. It may take a week or ten days to settle. The patient can be reassured. Intraocular haemorrhage (hyphaema) caused by a bleeding wound or iris is rare. If significant or the intra-ocular pressure is raised, medical or surgical intervention may be required.

Allergy to the steroid or antibiotic drops prescribed postoperatively may rarely cause a reaction. Itching, local erythema and oedema around the eye may occur. Stopping the drops or using 1% hydrocortisone cream will allow it to settle.

High pressure inside the eye. A pressure spike postoperatively is common and may be due to retained visco-elastic. It usually settles without treatment. Patients with pre-existing glaucoma are more susceptible; therefore a review and pressure check on the day after surgery is advised. If you are in a surgical camp or

Continues overleaf ➤

you have reasons to suspect that patients may not return for follow-up, a short course of a beta blocker, such as Timolol, may be given.

Low pressure inside the eye/leaking wound. A larger or poorly constructed wound may sometimes leak, causing the eye to be soft. The eyesight may be blurred and there is an increased risk of infection. Referral and resuturing are likely to be required.


A **flat anterior chamber** postoperatively occurs mainly due to wound leak. Low intraocular pressure and a Sidel test will confirm a leak. Small leaks usually resolve spontaneously and can also be managed medically using cycloplegia, aqueous inhibitors and antibiotics, and by reducing steroid therapy. Alternatively, a tissue adhesive or a bandage contact lens may be applied. More significant wound leaks may need reformation of the anterior chamber and suturing.

However, sometimes a shallow anterior chamber occurs with high intraocular pressure. This is usually due to blockage of aqueous humour flow due to pupillary block. Pupillary block may be associated with postoperative uveitis resulting in synechiae of the iris to the vitreous, posterior capsule or IOL. This can result in a shallow anterior chamber and high intraocular pressure. Placement of an anterior chamber IOL without a prophylactic peripheral iridectomy can also result in pupillary block. A surgical or laser peripheral iridectomy, accompanied with frequent steroids, is usually effective.

Clouding of the cornea may occur after excessive surgical manipulation or if there is a pre-existing corneal dystrophy. Usually gradual clearing is expected over a few weeks or, rarely, months. In the rare cases that the cornea does not clear spontaneously, corneal transplant surgery may be necessary. Before referral for corneal oedema, topical steroids, hyperosmotic agents and a contact bandage lens may provide relief. However if the eye has little or no potential for vision then a Gundersen conjunctival flap may be performed.

Decentration or dislocation of the implant (IOL) (Figure 1). If the IOL haptics (loops) have been incorrectly placed, the IOL may be decentred. If the operation was complicated and the posterior capsule ruptured, the IOL may

Figure 1. Decentred intraocular lens



have fallen back into the eye. In either case, blurred vision or pain may be experienced and further surgery may be necessary.

In many cases, the IOLs used are rigid, one-piece acrylic lenses. A decentred or dislocated intraocular lens may either be intracapsular or extracapsular. Intracapsular causes may be due to capsular phimosis or inadequate zonular support, e.g. in pseudo-exfoliation. Extracapsular decentration occurs when either one or both haptics (loops) are located in the sulcus with the optic in the capsular bag. On some occasions the optic may be tilted or displaced in front of the iris in the anterior chamber. Management in these cases comprises observation for asymptomatic cases or dialling the intraocular lens centrally and ensuring stability. In cases where the zonules are inadequate an anterior chamber lens may have to be placed, or a single-piece lens sutured to the iris or sclera.

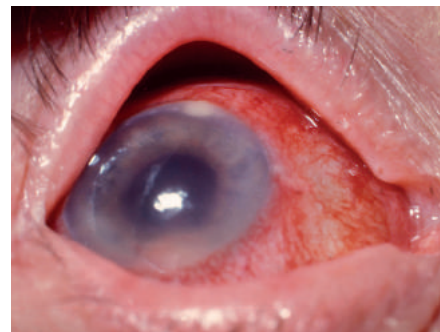
‘It is vital that patients monitor their own eye health and know where to go and what to do if they are concerned’

Incorrect power of the implant. Refractive ‘surprises’ (postoperative predicted errors greater than 2 diopters) occur in approximately 5% to 10% of lens implantations. Most are due to human error and are avoidable. Accurate preoperative biometry and strict adherence to protocol should prevent the wrong IOL being implanted. Refraction will reveal whether the IOL power has been miscalculated. Spectacle correction would normally allow the patient to benefit from the operation.

Postoperative refractive error is confirmed using retinoscopy and corrected using spectacles. This is usually done one month to six weeks postoperatively.

Infection in the eye (endophthalmitis) (Figure 2) is the most serious complication with an incidence that varies from

Figure 2. Endophthalmitis with hypopyon



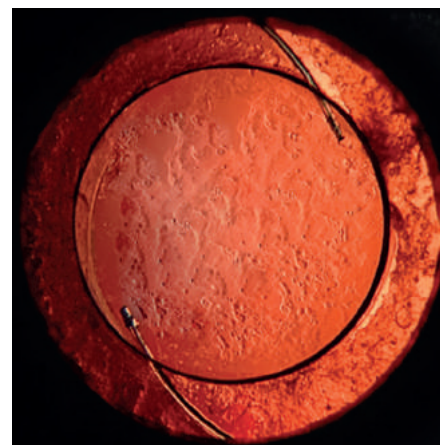
less than 1 in a thousand to several times that figure depending on the criteria of diagnosis, and whether the cases are culture-proven or clinically diagnosed.¹ When acute, it develops in 2–5 days with pain being a prominent symptom. However, endophthalmitis can present up to 6 weeks after surgery. Ciliary injection (redness around the cornea) and conjunctival chemosis occur, and pus in the eye (hypopyon) may be visible in the anterior chamber. Immediate referral for culture and intravitreal antibiotics may save the eye. Read more online: <http://www.cehjournal.org/article/postoperative-endophthalmitis>

Toxic anterior segment syndrome (TASS) is a mimic of endophthalmitis. It is a severe sterile postoperative inflammation due to contaminated solutions used in surgery. Topical corticosteroids are given until the inflammation subsides. Frequent follow-up is also essential to monitor symptoms and reassess for bacterial infection and intraocular pressure.

Late complications

These complications can occur after patients have gone home. It is therefore vital that patients monitor their own eye health and know where to go and what to do if they are concerned. A checklist of signs and symptoms can be sent home with patients.

Figure 3. Posterior capsular opacification



The basics of good postoperative care after glaucoma surgery



Cystoid macular oedema (CMO) is often the cause of unexpected visual loss and may become evident 4–6 weeks after surgery. It is more likely if the operation has been complicated, or there is diabetic retinopathy or pre-existing macular scarring. The majority of cases resolve spontaneously over weeks or months but with some loss of contrast sensitivity or, more significantly, poor vision. CMO is often treated with topical/sub-Tenon's or intravitreal steroids or non-steroidal anti-inflammatory drops. Surgical intervention is called for when there is an identifiable provoking cause, for example a vitreous wick, retained lens fragments or a decentred intraocular lens. As a precaution, most patients suffering from diabetic retinopathy or epiretinal membranes (pre-existing scarring at the macula) should be given anti-inflammatory medication as prophylactic treatment after their operation. The symptoms are blurred or decreased central vision.

Retinal detachment may occur weeks or months after surgery, more commonly in highly myopic people or after complicated surgery with vitreous loss. The symptoms may include 'flashes and floaters' and a peripheral 'shadow' across the vision. Refer immediately.

Posterior capsular opacification (PCO) (Figure 3) occurs in 10% of patients after two years and is the commonest reason for further intervention after cataract surgery. It is caused by lens epithelial cells migrating across the (normally clear) posterior capsule of the lens. It is treated with Nd-YAG laser in the eye clinic. In young people and children, opacification can occur early and patients should be warned that this may occur. The symptoms are blurred vision and glare.

Conclusion

The end of the operation is the beginning of an anxious period for the patient, when they are hoping that their sight will be restored. If complications have occurred the patient must be kept informed and the outlook must be explained to them. Postoperative symptoms should be heeded and signs carefully looked for in case intervention is required. Good preoperative counselling and awareness of postoperative problems will help to ensure that complications are detected early and managed effectively.

References

- 1 Alshihry AM (2014) Epidemiology of postoperative endophthalmitis (POE) in a specialized eye hospital. *Epidemiol* 4:145. doi: 10.4172/2161-1165.1000145.



Fatima Kyari

Ophthalmologist: Department of Ophthalmology, College of Health Sciences, University of Abuja, Nigeria.



Mohammed M Abdull

Ophthalmologist: Ophthalmology Department, Abubakar Tafawa Balewa University Teaching Hospital, Bauchi, Nigeria.

Glaucoma patients are treated by lowering the intraocular pressure (IOP) to a level that it is not harmful to the optic nerve. This prevents or delays loss of vision. Lowering of the IOP can be achieved through use of eye medication, surgery or laser procedures. The most common glaucoma surgery is trabeculectomy. This entails creating an additional passage for the drainage of the fluid inside the eye (the aqueous humour). The fluid drains from the anterior chamber, through an opening (fistula) in the sclera, to an artificially created reservoir (the bleb) under the conjunctiva. The bleb enables the fluid to be absorbed gradually into the systemic circulation and is hidden under the eyelid.

Before patients have a trabeculectomy, they must be informed that the operation will not cure the disease; it will lower the IOP in order to reduce the rate of deterioration of vision loss. They must understand that any vision already lost cannot be regained through surgery and that the surgery may cause

initial blurring of vision in the immediate postoperative period (and will resolve by itself over time).

Good follow-up care is essential, and patients should be provided with a contact number to call when they need to complain, ask for information or reschedule an appointment, or when they notice any symptoms that could indicate a complication.

Postoperative care after trabeculectomy can be classified into immediate postoperative care (0–6 weeks) and mid- to longer-term postoperative care (after 6 weeks).

Principles of immediate postoperative care (0–6 weeks)

Ensure that the aim of surgery has been achieved, i.e that the IOP has been lowered

One day after the operation (on day 1), the surgeon examines the eye to ensure that the operation is achieving drainage of aqueous humour with adequate formation of a bleb and satisfactory lowering of the IOP. The IOP on the first day postoperatively is not the final IOP, but serves as a good indication that a drainage channel has been successfully created. The surgeon also examines the eye to look for early complications at this stage: infection, hyphaema, conjunctival/wound leak, shallow/flat anterior

Continues overleaf ➤



Abdull Mohammed

Patients wait for their follow-up examination, which will include IOP measurement – an essential component of postoperative glaucoma care. NIGERIA

chamber, hypotony requiring intervention, and choroidal detachment.

Protect the eye from external injury

The operated eye is padded until the following day. If the other eye has no vision, the operated eye is not covered but a perforated eye shield is placed on it instead.

Ensure hygiene and prevent infection

The patient should keep the face clean and avoid touching the eye. Patients may bathe and shower, taking extra care not to bend forward or to touch the operated eye (which may also be protected with an eye shield). Hands should be washed before instilling any eye drops. Postoperative antibiotic eye drops (e.g. chloramphenicol) are prescribed for use 4–6-hourly or 4–6 times a day for 2–3 months.

Reduce inflammation associated with the operation

Some degree of redness and swelling may occur after the operation. Postoperative anti-inflammatory eye drops (e.g. dexamethasone) are prescribed for use 1–2 hourly during the first few days and subsequently reduced to 4–6 times a day. The postoperative eye drops may be used for 2–3 months as advised by the reviewing doctor.

Control pain

It is usual to have some eye pain after glaucoma surgery but this is often mild and responds to analgesics such as non-steroidal anti-inflammatory drugs and acetaminophen.

Symptoms and signs of complications (0–6 weeks)

A sudden loss of vision

A small reduction in vision, usually not more than 2 lines of visual acuity (VA), may occur after surgery, but should improve gradually or at least not worsen rapidly. Rapid deterioration of vision is an emergency; therefore it must be reported promptly. The following are common causes.

1 A hyphaema indicates the presence of blood in the anterior chamber. This clogs the trabecular meshwork and blocks the fistula created for drainage to the sub-conjunctival space, causing the IOP to rise, sometimes catastrophically. This increases damage to an already diseased optic nerve and may result in blindness if not promptly reported and treated. Patients should report to the health facility where they had the surgery for urgent management.



Lindsay Hampton

After a trabeculectomy, eyes require special care and protection from injury, e.g. wearing UVB sunglasses during the daytime. KENYA

Sudden loss of central vision may occur, especially in patients who had very severe disease at the time of surgery. Surgeons sometimes make a decision to avoid operating on such patients but instead offer other, less invasive, alternatives. Vision loss may be gradual or rapid, depending on the severity of disease and postoperative inflammation.

2 Choroidal detachment is caused by the passage of serum into the supra-choroidal space (between the sclera and the choroid) due to increased transmural pressure, most frequently caused by globe hypotony following trabeculectomy. It can present with quite severe loss of vision with variable degrees of pain. An urgent B-scan ultrasound can help with the diagnosis. Urgent treatment is needed to prevent permanent loss of vision.

Soft eye

This leads to a shallow or flat anterior chamber. It is usually caused by over-filtration due to a loose scleral trabeculectomy flap, a conjunctival wound leak at the incision site, or a leak via a conjunctival buttonhole. It may or may not present with reduction in vision, with little to severe pain depending on the cause. Padding the eye may be sufficient, but urgent surgery is sometimes necessary.

Redness, pain and discharge (pus)

This may be accompanied by a possible drop in VA very soon after surgery, and this combination is usually indicative of an active infection. Redness alone may be normal following surgery but if it persists beyond a few days it should be reported

as it may mean an active inflammation in the eye. All instances of the above symptoms should be reported urgently to the health facility where they will be investigated and properly treated.

Principles of longer-term postoperative care (after 6 weeks)

Optimise vision

Six to eight weeks after the operation, refraction should be undertaken to assess the patient's best-corrected visual acuity (BCVA) and to obtain a prescription for spectacle or contact lens correction. Not everyone can wear/continue with contact lenses following trabeculectomy. The doctor must assess the bleb and the suitability of contact lens wear.

Continue to protect the eye

Advise the patient about protecting their eye. Especially in sports, physical contact activity and windy weather, the eye needs to be protected from injury with sports goggles (where indicated) or UVB sunglasses during outdoor activities such as riding a motorcycle. The protective eyewear should be kept clean.

Continue medication

When necessary, the postoperative medication (antibiotics and steroid eye drops) may be continued for up to 3 months after surgery on advice of the doctor.

In some cases, anti-glaucoma medication may also be prescribed after the operation, if the lowering of the IOP to the desired level has not been achieved. Patients should be made aware of this possibility before surgery.

Be alert for signs of postoperative complications

The patient must be monitored regularly to detect any changes in vision, pain or any other symptoms that will indicate postoperative complications such as infection, a failed bleb or overfiltration. The importance of community-based follow-up by the community health worker or ophthalmic nurse cannot be overemphasised; this is essential in order to ensure that symptoms and signs are recognised and treatment offered without delay. Patients should be advised to get help if they notice any symptoms – see panel below.

'The importance of community-based follow-up by the community health worker or ophthalmic nurse cannot be overemphasised'

Possibility of additional surgical procedures

When the IOP control is not at the desired level, the doctor may advise additional procedures to optimise IOP control. These procedures may include the release of releasable sutures, bleb revision, antimetabolite injections or even laser procedures.

Symptoms and signs of complications in the longer term (after 6 weeks)

- 1 Redness associated with discharge (pus) from the eye.** Long after a successful trabeculectomy, bacterial infection could occur. A person who has had eye surgery and has discharge (pus) from the eye needs to be seen immediately by an eye doctor and treated with the appropriate medication. Self-medication, especially with steroid eye drops, must be avoided. Serious consequences and loss of vision could occur if there is endophthalmitis.

- 2 Discomfort.** A large drainage bleb may cause abnormalities in tear spread over the cornea, causing poor tear films that cause a sensation of dryness and discomfort. Such large blebs may also be uncomfortable under the eyelid causing cosmetic embarrassment.

- 3 Cloudy vision and cataract.** The chance of an eye developing a cataract increases after trabeculectomy. The patient should be made aware of this. The patient may have increasing glare in bright sunlight or while driving at night. Any reduction in vision must be investigated to determine the immediate cause. Vision generally improves following cataract surgery, except if the glaucoma damage is significant.

- 4 Changes in refraction:** There may be astigmatism following trabeculectomy because of the mild distortion of the eye's anatomy. This may manifest as a need for new spectacles. Such change can be delayed until about 3 months after the operation, when the eye has stabilised.

- 5 Continued loss of vision:** Even with good IOP control, patients may still continue to lose vision. The patient may see haloes around light bulbs which may indicate cloudiness of the cornea due to raised IOP. Glaucoma surgery reduces the rate of loss of vision in glaucoma patients but may not completely halt it.

Advice for patients at discharge

Patients should be given information about the following before they go home after a trabeculectomy. They should also understand about the possible complications and understand the importance of getting help urgently so that their vision can be preserved. Make sure that patients have the contact information they need, e.g. the telephone numbers of the appropriate person so that they can get an appointment as soon as possible.

How the eye will feel

You may have some watering, sandy sensation or blurring of vision after trabeculectomy, but this should clear within a few days. Soreness and irritation may occur from the sutures or because of the surgery itself. These sensations generally reduce within a few days.

Protection

The eye has now been operated on and is more fragile than before. It is important to take special care and to protect your eye from injury. You can wear UVB sunglasses in the daytime.

Caution with activity

Physical activities that require bending forward such as farming, 'ruku' and

'sajda' (prostration) during Muslim prayer and lifting of heavy items are to be avoided in the first six weeks after surgery. Strenuous activities such as running, jumping, swimming and sex are also to be avoided until the eye doctor advises it is safe to resume them.

Cleanliness and hygiene

- You can shower, have a bath or wash your face to ensure cleanliness.
- For at least one week, do not use eye make-up, including kohl and eye pencil.
- Avoid touching the eye directly or rubbing it.

Medication

- Wash hands before applying your eye drops.
- Do not touch the tip of the dropper of the eye drop bottle with fingers and do not allow the tip of the bottle to touch the eye
- Use the eye drops as often as indicated on the bottle or as directed by your doctor.

Keeping appointments

It is important to keep your appointment, as the eye doctor will need to regularly monitor your vision and eye pressure

and look out for any signs of complications. Bring your eye drops with you to the hospital.

IMPORTANT: Come back in case of any worrying signs or symptoms

Contact your community health worker (if you have one) or your eye nurse or eye doctor immediately if you experience any of the signs or symptoms listed below – even if this is several months after the operation – as these can indicate that there is a problem that needs to be looked at. Coming back quickly will give medical professionals the best chance to save your sight and your eye.

- Any pain: come back very urgently
- A rapid reduction in vision (particularly central vision): come back very urgently
- Redness and/or discharge (pus): come back very urgently
- Haloes around light bulbs: come back very urgently
- Blurry or distorted vision (including increased glare in sunlight or while driving at night): less urgent, but can easily be corrected with a cataract operation or a new spectacle prescription.



Postoperative care for paediatric cataract patients



Dr P Vijayalakshmi
Chief: Paediatric Ophthalmology & Strabismus Department, Aravind Eye Hospital, Madurai, India.



Lucy Njambi
Lecturer and paediatric ophthalmologist: University of Nairobi, Nairobi, Kenya.

Alongside good quality care before and during a cataract operation, careful postoperative care and long term follow-up are essential for good outcomes in children undergoing cataract surgery. This is only possible with the active and ongoing involvement of parents. By giving their child the medication prescribed for them, at the correct times, parents play a vital role in helping the eye to heal well and reducing complications. By bringing their child back for refraction and regular follow-up appointments, parents help to ensure a good visual outcome. Every effort should be made to support parents, for example:

- Even before the operation, discussing with them the important role they have to play.
- Giving them oral and written information regarding medication and follow-up visits before they leave the hospital.
- Putting in place a system or personnel to track patients and send reminders about medication compliance and appointments.

For the eye team, it is important to be aware of children's particular postoperative needs. Children's eyes are different from adults' eyes, and are more prone to severe inflammation (uveitis) and a shallow anterior chamber after cataract surgery.

Accurate refraction is critical because of the risk of amblyopia, but correction is more complex in young children as their eyes continue to grow and their refractive status can change over time. The risk of opacity of the visual axis, and the risk of glaucoma, are also far greater in children than in adults. As with adult cataract surgery, endophthalmitis can also occur, but is rare.

In this article, we look at the postoperative care required at various stages, and on page 34 we discuss complications, amblyopia, surgery on the second eye and insertion of a secondary IOL.

Immediately after surgery, in the recovery room

Personnel working in the recovery room must pay attention to the child as well as the operated eye. An eye shield should be secured in place to protect the operated eye. Pain and vomiting must be controlled as both can raise the intraocular pressure, leading to a shallow anterior

chamber and/or displacement of the IOL.

After safe extubation, vital signs should be monitored for 60–90 minutes in a designated postoperative recovery room. The recovery room should have well trained staff and have a controlled

'Personnel working in the recovery room must pay attention to the child as well as the operated eye'

temperature, with a well equipped system for oxygen administration, pulse oximetry, cardiac monitoring and suction. Fever and shivering after general anaesthesia are common. The child should be kept warm, using a warmer for very young infants, and should be placed on her or his side with

the operated eye uppermost. Fever can be managed with paracetamol syrup. Oxygen saturation and pulse rate should be monitored and the child observed for signs of respiratory distress, nausea or vomiting. An anaesthetist or anaesthesia technician trained in the care of young children should always be available.

Once the child has completely recovered, she or he can be moved to the ward. Parents must be told how and when to feed the child and how to avoid choking (which can increase pressure in the eye).

On the ward

On the ward, the child should be observed for restlessness, irritability or crying (which is usually due to pain). It is

Figure 1. The 'flying baby' method for examining a baby at a slit lamp when there is no portable slit lamp available

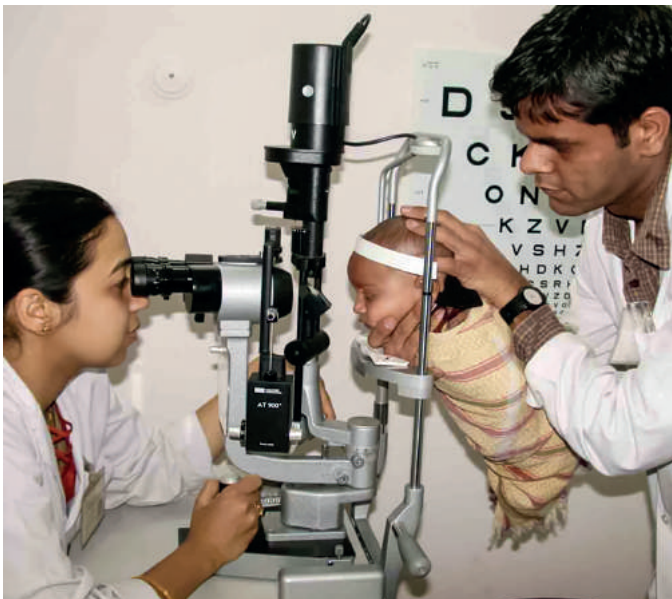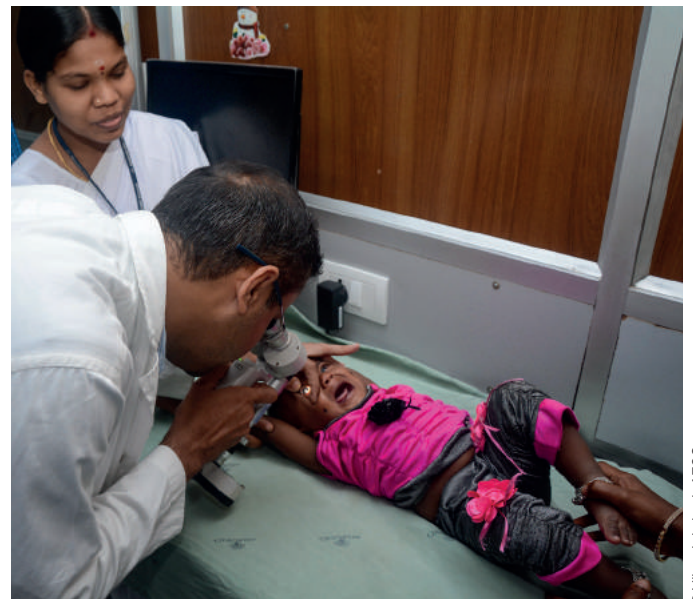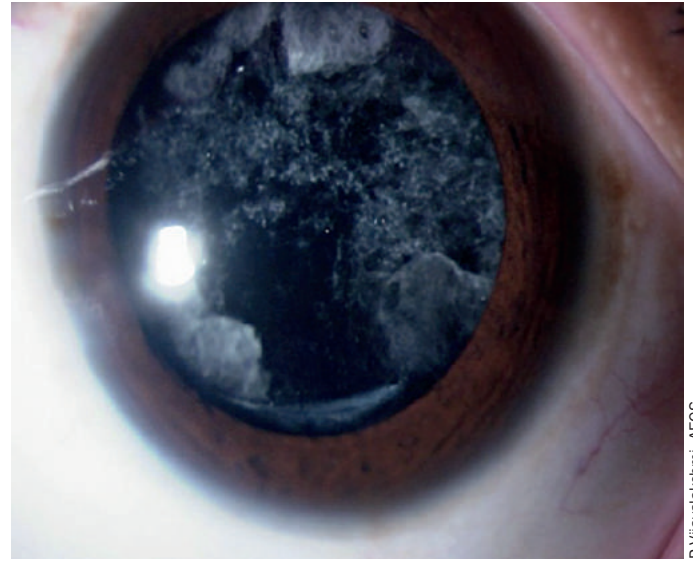
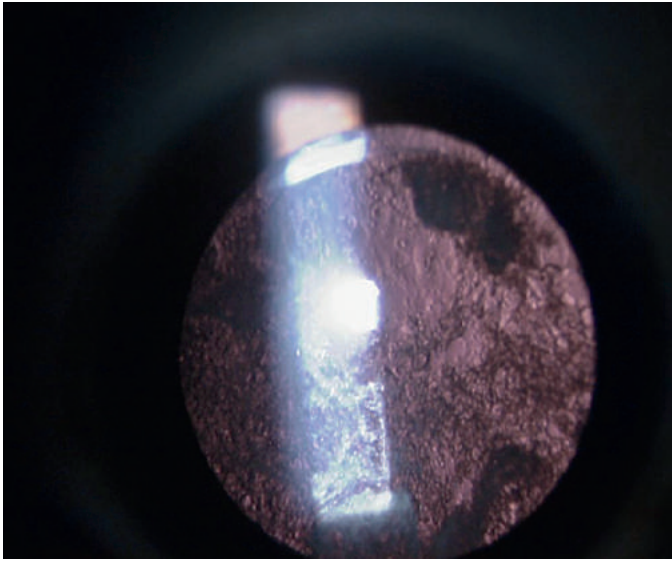


Figure 2. Using a portable slit lamp to examine a young child.



Ravi Thomas

P Vijayalakshmi, AECS



Paediatric cataract viewed using a slit lamp (left) and a diffuse light (right)

important to control pain as crying can also raise the intraocular pressure or the child may vigorously rub the eye.

Routine examination on the first and second postoperative days should include the status of the wound, corneal clarity, anterior chamber reaction and depth, patency of the peripheral iridectomy (if performed), clarity of the visual axis, details of IOL placement and adequacy of pupil dilation. Parents should be asked if their child has shown signs of pain or discomfort.

Even young infants can be examined using a standard slit lamp, using the 'flying baby' method (Figure 1). A hand-held slit-lamp can be used if available (Figure 2). A hand-held light source, shone obliquely into the eye, can also be used to assess the anterior segment. The structures can be magnified using a 20- or 30-dioptre lens.

A minimum in-patient stay of two days is recommended for uncomplicated cases. The stay can be longer if there is intense postoperative inflammation or other complications and for those who may not come back for follow-up.

Two examples of routine topical medication (from day 1 after surgery) are given in the panel. Parents must be properly counselled so they understand how important it is to comply with medication, especially in the early postoperative period. Parents need to be shown how to instil the medication, which may entail showing parents how to swaddle their child and gently open the eye. Nursing staff need to be sure that parents can do this safely and reliably before the child is discharged.

Control of inflammation

Systemic steroids are indicated if increased inflammation is anticipated (in cases of traumatic or complicated cataracts), or if there was severe inflam-

mation following surgery on the first eye. A single dose of intravenous dexamethasone (4 mg per 25 kg of body weight) at the end of surgery helps to reduce inflammation. If severe inflammation persists after surgery, oral prednisolone can be used (0.5 mg to 1.0 mg per kg body weight) titrated according to the severity of inflammation and administered on a daily basis for the first 15 days, followed

by the same dose on alternate days for the next 15 days.

An alternative is a single dose of subconjunctival or peribulbar triamcinolone 20–40 mg given at the end of surgery, especially when compliance is not guaranteed, or in younger children who cannot take oral medication. In many centres this is routine practice.

Continues overleaf ➤

Postoperative medication (topical)

Example 1 India

Non-IOL surgery

- **Antibiotics and steroids:** For children under 12 months, use an antibiotic-steroid combination in ointment form (tobramycin and dexamethasone, or moxifloxacin and dexamethasone) 3 to 4 times a day, reducing over 6 weeks. For children over 12 months, give the same combination in eyedrop form according to the same schedule.
- **Dilation:** For children under 12 months, give atropine eye ointment once a day for 1 week, then twice a week for 3 weeks and finally once a week for 2 more weeks. For children over 12 months, use homatropine or cyclopentolate eyedrops according to the same schedule.

IOL surgery

- Give steroid eyedrops (predforte acetate 1%) 6 times a day, tapered over 6 weeks.
- Give antibiotic eyedrops (tobramycin or moxifloxacin) 4 times a day for 2 weeks, 3 times a day for the next 2 weeks and then twice a day for 2 more weeks.
- Dilating drops (homatropine eyedrops 1%) once a day for

2 weeks, and then every second day for 2 more weeks. Use ointment if the drops are too difficult to administer.

Example 2 Kenya

For both IOL and non-IOL surgery, the following regime is followed.

- **Topical steroid drops** (dexamethasone or prednisolone): initially 2-hourly for 2 weeks, then 4-hourly for a month, and finally tapered over another month if there is no evidence of inflammation. IOP monitoring is mandatory to check for steroid response.
- **Topical antibiotic drops** (chloramphenicol, tobramycin, quinolones): 4 times daily for 4 weeks.
- **Combined steroid and antibiotic preparations** can be used as an alternative, especially where drug availability, administration and compliance are an issue.
- **Ointments** can be used at night to enhance drug concentration and in those who are non-compliant with drops.
- **Atropine 1% drops:** once to twice daily for 2–4 weeks. For children younger than one year old, apply once daily or use the 0.5% preparation.

On the day of discharge

The following should be checked:

- Visual acuity (if possible)
- Intraocular pressure (with a non-contact tonometer). It is important to avoid applying pressure on the eye as this can lead to an erroneous reading and can put pressure on the wound, leading to shallowing of the anterior chamber.
- Red reflex (using a direct ophthalmoscope)
- Posterior pole of the fundus (using an indirect ophthalmoscope).

After discharge, children are encouraged to wear dark glasses (sunglasses) for both protection and comfort.

Initial follow-up

Children with complications should be reviewed weekly until improvement is noted.

The first follow-up visit for uncomplicated cases must be within 2–4 weeks after surgery. If possible, children should undergo refraction at this first postoperative visit; this minimises travelling for the parents and reduces the likelihood of missed follow-up appointments. Children undergoing cataract surgery (with or without IOL), should be dispensed spectacles within 2 weeks of cataract surgery. In older children who have undergone IOL surgery, the prescription of spectacles can be delayed until 4 weeks after surgery to allow the wound and refraction status to stabilise. (Where follow-up is uncertain, however, it is better to dispense spectacles on discharge). Remind parents about the importance of compliance with the prescribed eyedrops. Find out if they have any problems and support them to find solutions.

Optical correction: non-IOL surgery

Prescribe single lenses, focusing on near vision until the age of 18–36 months and bifocals after that. Contact lenses are another option. Children older than 3 years benefit from bifocals with a +2D add. A flat top D-shape or executive bifocal are preferred in children as they give a wider field of view and less distortion (Figure 3); however, they may not be readily available with the high plus lenses required by children with aphakia. Although progressive lenses give very good visual quality, they are expensive and not recommended for children as their spectacles need to be changed very frequently.

Optical correction: IOL surgery

Any residual refractive error, especially astigmatism, should be corrected with an

appropriate near vision addition, either in the form of bifocals or progressive lenses (depending upon the affordability) at the first postoperative visit. At each visit, compliance with spectacle wear should be discussed and any issues resolved. In cases of children with disabilities, this should be done with extra care, always encouraging the parents towards better compliance.

Longer-term follow-up

Longer-term follow-up visits should take place every 3 months up to 2 years of age, every 6 months up to 5 years of age and thereafter yearly or as indicated until the child reaches maturity.

At each visit, the examination should include assessment of the visual acuity, refraction, and slit lamp examination for anterior segment details including IOL placement, pupil shape, clarity of the visual axis, any anterior chamber reaction, and measurement of intraocular pressure (using non-contact methods). Axial length measurement (especially in unilateral cataract or anisometropia) and fundus examination are also essential. Ocular motility and alignment should be assessed so that strabismus and/or amblyopia can be detected early.

Medication and advice (e.g patching) should be adjusted according to the findings. Extended medication should be given to those who may not return for follow-up due to travel logistics or financial constraints. Many families need reminders and special help (reimbursement) for follow-up. It is useful to have one dedicated person in the team to monitor this.

Figure 3. A Bangladeshi child wearing executive bifocal spectacles after bilateral cataract surgery.



Clare Gilbert

Paediatric cataract: challenges and complications



Dr P Vijayalakshmi

Chief: Paediatric Ophthalmology & Strabismus Department, Aravind Eye Hospital, Madurai, India.



Lucy Njambi

Lecturer and paediatric ophthalmologist: University of Nairobi, Nairobi, Kenya.

Detection and management of amblyopia

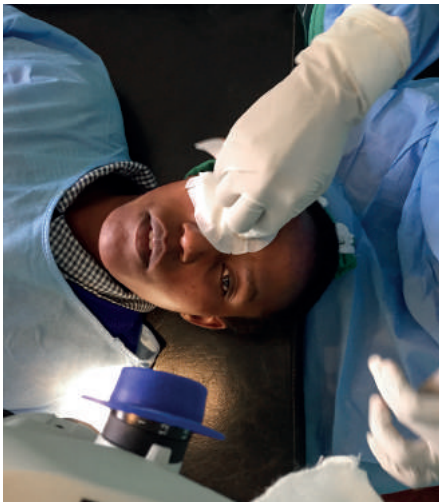Amblyopia should always be anticipated in children with unilateral cataract, asymmetrical bilateral cataracts (or where there is a delay between the first and second eye operation, or a delay of more than a year between diagnosis/detection and surgery), cataracts with anisometropia or traumatic cataracts with corneal scars. When amblyopia is detected, occlusion therapy (eye patching) must be instituted at the earliest opportunity. The patching regimen is the same with any strabismic amblyopia and sometimes needs to be aggressive at the start. It is crucial to explain the need for patching to the parents, since compliance is the greatest obstacle to the success of amblyopia treatment.

Myopic shift

As all children are prone to a myopic shift, the axial length should be measured at every visit. A more rapid shift is seen in those operated early in life with emmetropic correction in infancy. Frequent refraction is necessary for optimal optical correction. Children under the age of 8 years undergoing IOL surgery should be slightly under-corrected, leaving them slightly hyperopic so that they can grow into emmetropia, thereby preventing very high myopia later.

Management of low vision

Even with uncomplicated cataract surgery and a clear visual axis, some children still end up with low vision due to amblyopia or other ocular or central nervous system abnormalities such as cerebral palsy, periventricular leucomalacia, congenital rubella syndrome, etc. These children should be referred for vision rehabilitation.



Applying an eye pad after cataract surgery. KENYA

Secondary IOL

A decision about whether to insert a secondary IOL in aphakic patients should be considered with caution, taking into account the status of eyeball growth (especially the anterior segment), glaucoma, posterior capsule support, and the potential to improve visual acuity. The sulcus is the easiest position for secondary lens implantation, although this has a higher risk of decentration. With the availability of improved technology and various lenses, each child who is in need should be given a choice, provided the parents understand the visual prognosis.

Timing of the second eye operation

In infants under the age of 12 months with bilateral cataracts, the risk of amblyopia is very high after non-IOL surgery. Surgery on the second eye is recommended 2 to 3 days after the first eye during the same admission (total admission 5–6 days). Where anaesthesia risk is high, both the eyes can be operated in a single sitting.

If the parents of children undergoing IOL surgery are poorly resourced or have travelled a long way and may not come back for an operation on the second eye, then this can also be done a few days later, as most inflammation is seen within the first few days after surgery.

Bilateral surgery is becoming increasingly common in some countries, particularly in centres with limited access to a paediatric anaesthesiologist and when parents may not return for surgery on the second eye. Another consideration is the lower risk of repeated general anaesthesia. Strict aseptic measures must be observed to reduce the risk of bilateral endophthalmitis. Each eye is treated as a separate procedure with repeat scrubbing, gowning and gloving of

the surgeon and assistant. A new sterile instrument set must be used for the second eye. Contraindications include upper respiratory and ocular infections, congenital nasolacrimal duct obstruction and children at risk of increased inflammation such as those with juvenile rheumatoid arthritis.

Complications

Visual axis opacification

Visual axis opacification and membrane formation is common, particularly in young children. For significant opacity, i.e. with reduced visual acuity or where fundus details cannot be seen, YAG capsulotomy can be tried. Surgical membranectomy is required if YAG is not available or fails, or if a soft after-cataract (secondary cataract) has developed. This is best avoided by doing a primary posterior capsulotomy and anterior vitrectomy up until the age of 6–9 years. In older children, a prophylactic Nd:YAG laser capsulotomy can be done at the one week or one month follow-up, when the posterior capsule is unlikely to be fibrosed.

Glaucoma

Glaucoma is common in children after surgery for congenital cataract and is difficult to manage. It is more frequent with microphthalmos, microconea, congenital rubella syndrome, anterior segment anomaly (such as aniridia, ectopia lentis, or spherophakia) and in traumatic cataract and those operated for cataract in infancy. It can occur many years after the operation. IOP measurement and recording is therefore

mandatory at all visits and central corneal thickness should be measured where indicated. Anti-glaucoma medication should be prescribed after consultation with a glaucoma expert. Apart from a rise in intraocular pressure, other important signs of glaucoma are an increase in axial length, rapid loss of hypermetropia or an increase in myopia and optic disc cupping.

Postoperative uveitis

The incidence of severe postoperative uveitis has reduced with better surgical techniques, modern IOLs, in-the-bag placement of IOL, and less manipulation of the iris. Heparin-coated IOLs or intracameral heparin, where available, can also reduce the risk of uveitis. Early and frequent use of topical, periocular and systemic steroids in some cases can usually control the inflammation.

The trick is to ensure an in-the-bag placement of the IOL to minimise IOL and iris touch and subsequent iris chafing.

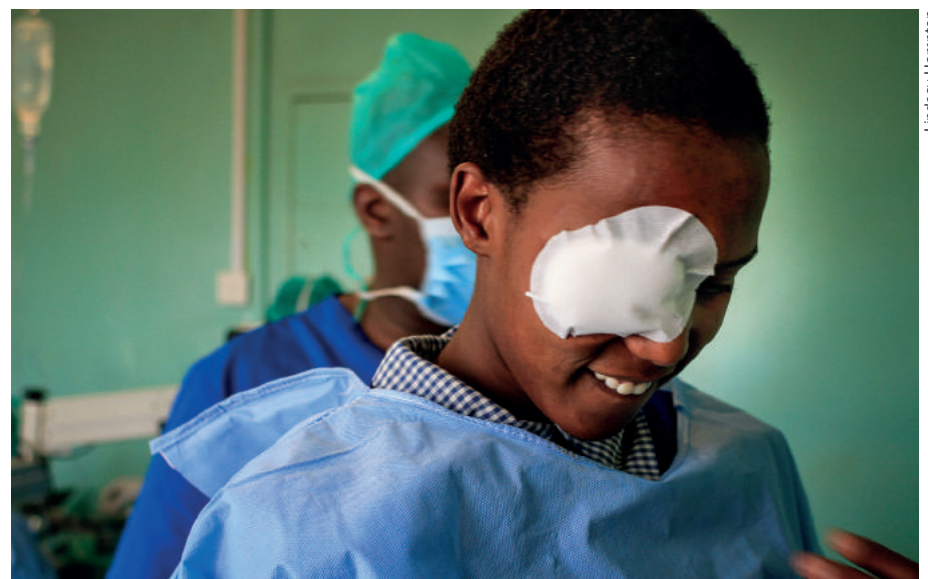Retinal detachment

Although retinal detachment is rare the retina should be examined at each visit particularly in eyes with long axial lengths or where surgery was complicated. Retinal examination can be challenging due to small pupils and peripheral capsular opacities.

Endophthalmitis

Treatment for endophthalmitis in children is in principle the same as for adults. After surgery, loose sutures should be removed as they predispose to infection.

‘Glaucoma is common in children after surgery for congenital cataract’



A 13-year-old girl after cataract surgery. Good postoperative care is essential in order to avoid complications. KENYA

Cleaning and dressing the eye after surgery



Sue Stevens

Former Nurse Advisor, Community Eye Health Journal, International Centre for Eye Health, London School of Hygiene and Tropical Medicine, London, UK.

1 Cleaning the eyelids

Before you start

- Wash your hands (and afterwards too).
- Wear gloves if available/required.
- Position the patient comfortably with head supported.
- Avoid distraction for yourself and the patient.
- Ensure good lighting.
- Explain to the patient what you are going to do.

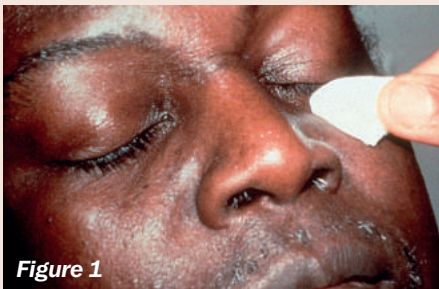You will need

- Sterile gauze swabs.
- A pre-made salt solution suitable for eyes, if available. You can make up your own: dissolve 1 heaped teaspoonful of salt or sodium bicarbonate in a jug containing 500 ml of boiled water (half a litre) and allow the solution to cool.
- Pour a very small amount of the solution into a small sterile pot on a clean surface.

Method

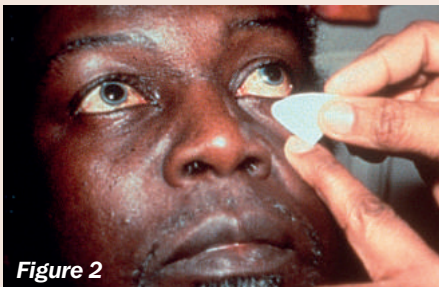1 The eyelashes

- Ask the patient to close both eyes.
- Take a folded gauze swab.
- Moisten the swab with the prepared solution.



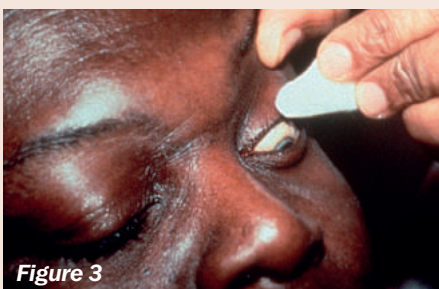Pak Sang Lee

Figure 1



Pak Sang Lee

Figure 2



Pak Sang Lee

Figure 3

- With the swab, gently clean along the eyelashes in one movement, from inner to outer canthus (Figure 1).
- Discard the swab after use.

2 The lower eyelid

- Ask the patient to look up.
- With one hand, take a new swab and moisten it in the solution.
- With the index finger of the other hand, gently hold down the lower eyelid.
- With the swab, gently clean along the lower eyelid margin in one movement from inner to outer canthus (Figure 2).
- Discard the swab after use.

3 The upper eyelid

Note: Extra care is needed when cleaning the upper eyelid margin. Try to keep the cornea in view throughout and avoid touching it with the swab.

- Ask the patient to look down.
- With one hand, take a new swab and moisten it in the solution.
- With the thumb or a finger of the other hand, gently ease the upper eyelid up against the orbital rim (just below the eyebrow), taking care not to put any pressure on the eyeball.
- With the swab, gently clean along the upper eyelid margin in one movement from inner to outer canthus (Figure 3).
- Discard the swab after use.

Note: always use a new swab each time

- If the eyelids are very sticky or encrusted, it will be necessary to repeat any part of the above procedure (using a clean swab every time) until all debris or discharge is removed.

Finally, discard the unused remainder of the solution.

2 Applying a postoperative dressing

You will need

- An eye pad
- An eye shield
- Scissors
- Adhesive tape

Preparation

Remind the patient not to open the affected eye under the pad. If the eyelids do not close naturally over the cornea it will be necessary, before padding, to tape the eyelids closed.

Method

- Use a commercially available eye pad or make your own: place cotton wool between two pieces of gauze and cut into an oval shape approximately 5 centimetres wide and 6 centimetres long (Figure 4).

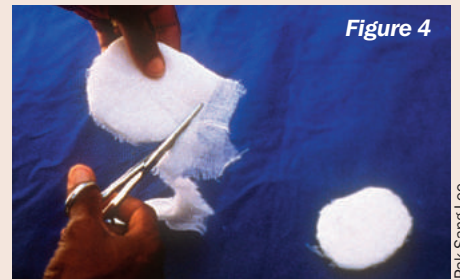


Figure 4

Pak Sang Lee



Figure 5

Pak Sang Lee

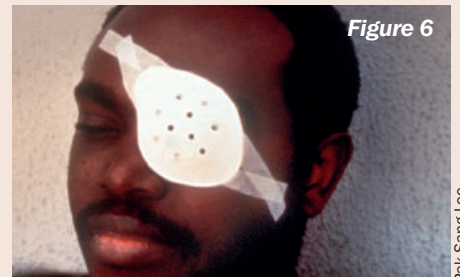

Figure 6

Pak Sang Lee




Figure 7

Pak Sang Lee

- Apply a piece of adhesive tape, about 15 cm long, to the eye pad (Figure 5).
- Ask the patient to close both eyes.
- Position the eye pad diagonally over the closed lids of the affected eye and tape firmly, but gently, to the forehead and cheek.
- Apply a second and third piece of tape to ensure the pad lies flat.

Extra protection can be given by taping a shield over the pad in the same way. The shield in Figure 6 is produced commercially and is called a Cartella shield. You can also make your own. Use a round object to draw a circle approximately 8 cm in diameter on thin cardboard or a used X-ray film and cut around it. Make a single cut into the centre (just half the diameter). Turn into a cone (Figure 7) and secure the shape with adhesive tape.

Before discharge, show patients how to instil their own eyedrops. This article shows you how: www.cehjournal.org/article/instilling-your-own-eye-drops/

Understanding and caring for a lensmeter



Ismael Cordero

Clinical Engineer, Philadelphia, USA.
ismaelcordero@me.com

A lensmeter or lensometer is an instrument used to verify the prescription of eyeglasses or spectacles. Many lensmeters can also verify the power of contact lenses with the addition of a special lens support. The values obtained from a lensmeter are the values specified on the patient's eyeglass prescription: sphere, cylinder, axis, add, and in some cases, prism. It is commonly used prior to an eye examination to obtain the last prescription the patient was given, in order to expedite the examination.

In one commonly used type of lensmeter the target seen through the eyepiece consists of a set of three wide lines with wide spacing between them and another set of three narrow lines with smaller spacing between them. These two sets of lines intersect at right angles. The closely spaced lines represent the sphere component of lens power and the thicker, widely spaced lines represent the cylinder power. In the case of a spherical lens, all of the lines of the target will focus at the same time, while in the case of a sphero-cylindrical lens, the lines will focus separately at different power drum readings (see illustration).

In another type of lensmeter, a series of light dots forming a circle is used as a target instead of the two sets of parallel lines described earlier. If a spherical lens is measured, the circle remains a circle

and the power drum is adjusted to obtain a sharp image of the dots. For spherocylindrical lenses the dots, when focused, will display a sharp ellipse. The major and minor axes of the ellipse can be read on the scale provided in the instrument.

The target is imaged through a lens. The eyeglass lens under test is placed at the rear focal point of this lens. Light emerging from the spectacle lens enters the eyepiece which contains a reticle. The reticle is a permanently etched series of concentric rings used to measure and locate the prism base direction, and also contains orientation lines for each lens meridian and a protractor scale.

For measuring the power of the lens, the power drum is turned until a clear and sharp image of the target is seen through the eyepiece. The power (in diopters) can be read on the scale on the wheel. For measuring the focal power of cylindrical and spherocylindrical lenses that have different powers in different meridians, the optics of the equipment can be rotated by turning the axis wheel. The angular position can be read on the circular scale of the axis wheel.

The eyeglass lens to be tested should be placed on the lens stop so that the outside of the lens is facing the eyepiece and the side of the lens that sits closest to the user's eye is facing the instrument's light source.

Before using the instrument, you should look through the eyepiece. The reticle should be in focus. If it is not, adjust the eyepiece until it is sharply focused.

Checking power calibration

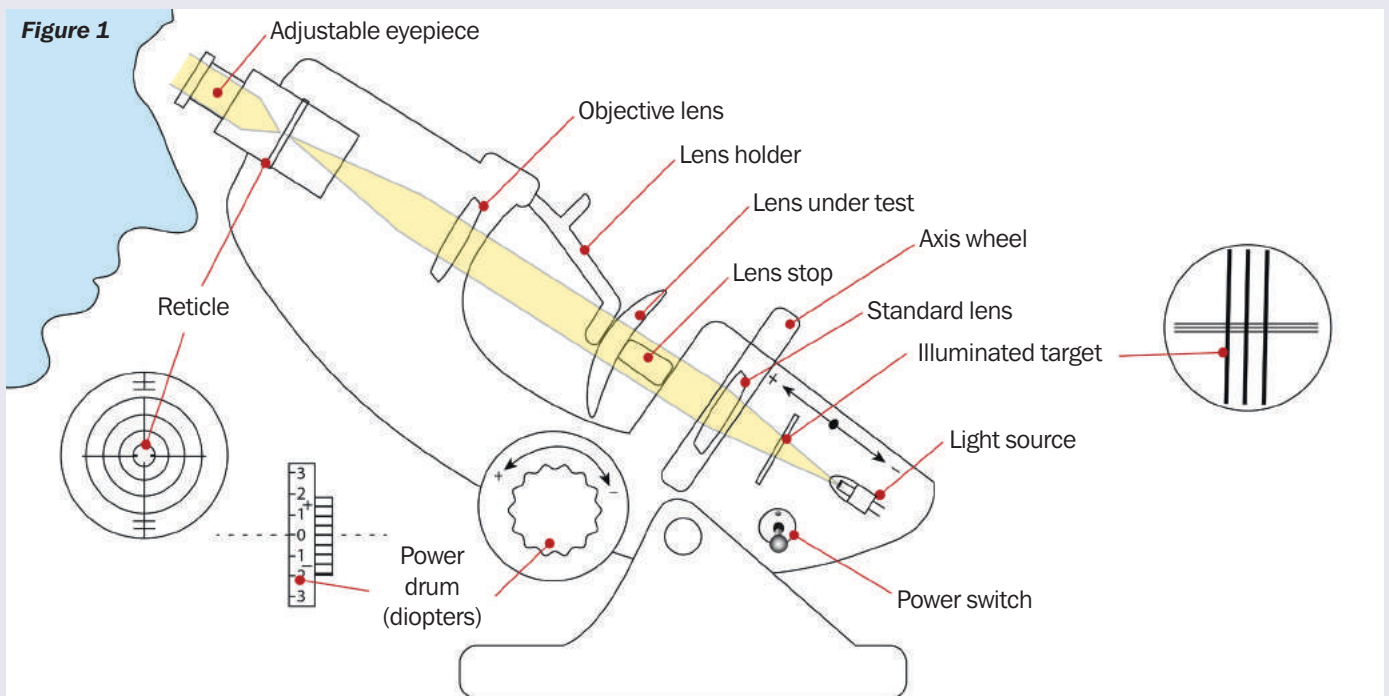
Periodically ensure that the power calibration of your lensmeter is accurate by following these steps:

- Turn on the lensmeter.
- Turn the eyepiece ring so that the reticule appears in focus.
- Turn the power wheel into the plus, then slowly decrease the power until the lensmeter target is sharply focused. Do not oscillate the wheel back and forth to find the best focus. The power wheel should read zero if the instrument is properly calibrated.
- If the power wheel does not read zero, re-focus the eyepiece and re-check the calibration. If the power wheel still does not read zero, the error must be compensated for in all future measurements made with the lensmeter, or the lensmeter needs maintenance. (Note: subtract the calibration error from the power measurement to compensate for calibration errors.)

General care

- If dust falls onto the surface of the lenses of the lensmeter, blow it off with a clean bulb syringe, a dust brush or compressed air.
- Wipe the instrument's exterior with a soft cloth to prevent dust accumulation.
- Do not attempt to lubricate the instrument. If it feels tight, contact a qualified service technician.
- To prolong the life of the bulb, do not leave the instrument on all day.
- Cover the lensmeter when not in use to protect it from dust.

Figure 1



Ismael Cordero

Postoperative care in trichiasis surgery



Esmael Ali

Research Fellow: International Centre for Eye Health, London School of Hygiene and Tropical Medicine, UK

Postoperative care is an important aspect of trichomatous trichiasis (TT) surgical services. Follow-up visits should ideally take place on the first postoperative day (to remove the eye patch), after 8–14 days (to remove sutures; optional if absorbable sutures are used), at 3 months (to re-examine the operated lid for intermediate surgical outcomes), and then at or after six months.

An eye patch must be applied after surgery and should stay on overnight to prevent unconscious disruption of the wound by the patient while asleep. When removed the following day, the wound should be cleaned using gauze and normal saline and the operated eyelid should be examined. If the patient is not able to attend the first postoperative day follow-up visit, then she/he should be advised to do the following at home:

- Clean hands with soap and water. Carefully and gently remove the patch and then clean the operated eye starting from the nasal side in a horizontal stroke using clean towel and warm water, and soap if available. Tell

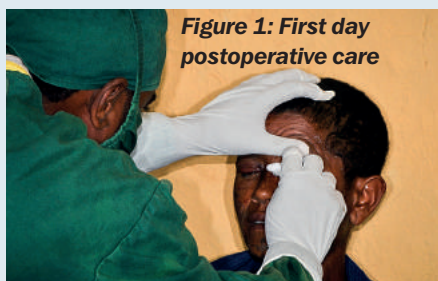

Figure 1: First day postoperative care

Esmael Ali

the patients that the operated eyelid will appear swollen, but that this is normal.

- Use light pressure only.
- Dry with clean towel or cloth and then apply tetracycline eye ointment between the lower eyelid and the eyeball twice daily for two weeks.

Patients may resume day-to-day activities on the second postoperative day. It is important to say this to the patients preoperatively as fear of not being able to work after surgery is among the main reasons deterring patients from accepting trichiasis surgery. However, they should be advised about the importance of keeping the wound clean and avoiding frequent contact with unwashed hands. Activities that may excessively expose the operated eyelid to dust should be avoided for few days. In some trachoma areas there is a

belief that the smoke from a fire during cooking 'would make the trichiatric lashes return'. Patients should be advised that they can resume cooking, however they should know that the fire smoke may create irritation and itchiness in the eye. They must avoid touching the eye and rubbing it as this may introduce infection as well as disrupt the surgical sutures and correction.

Patients should be advised to come back to the clinic if any of the following occur.

- Postoperative bleeding (visible through the patch or after it has been removed).
- Signs of infection such as sustained swelling, redness, pain, fever or an itching sensation and discharge on the operated lid.
- A sensation of stabbing pain or discomfort and excessive tearing. This is usually due to a suture fragment or a broken eyelash tucked into the tarsal conjunctiva during the time of surgery; this would constantly rub the cornea and/or conjunctiva during blinking.
- The presence of any lashes touching the cornea at any time after surgery.
- When the operated eyelid does not close properly or there is an eyelid contour abnormality or uncosmetic irregularity.
- Granuloma, a sessile fleshy growth on the tarsal conjunctiva that may occur between 1 and 6 months after surgery.

Tropical Data: a new service for generating high quality epidemiological data

Tropical Data – a WHO-led service helping national programmes collect and achieve more with their data – was launched on July 20, 2016.

Good quality prevalence data are essential for countries to plan, implement and monitor programmes attempting to eradicate, eliminate or control tropical diseases. The trachoma community has just completed the Global Trachoma Mapping Project, the largest infectious disease mapping effort ever completed, involving the examination of 2.6 million people. Now, the systems and methodologies used for the Global Trachoma Mapping Project have been further refined to create Tropical Data. Tropical Data supports countries to develop population-based survey protocols that are consistent with WHO recommendations, train and certify field teams using standardised training materials and certified trainers, create appropriate budgets, project-manage training and fieldwork, maximise the fidelity of data capture in the field through use of a purpose-built Android smartphone-based app, secure data through



© Shea Flynn / RTI International / Tropical Data

An inter-grader agreement test for Tropical Data Master Graders. SENEGAL

encryption (both at rest and in transit) apply built-in data quality assurance and quality control processes, independently and consistently clean data (with logging of all changes and retention of original raw datasets alongside cleaned ones), automatically analyse cleaned data to generate key prevalence metrics, maintain country ownership and control of data (with constant password-protected access of health ministry-designated officials to their data from the moment that they are uploaded and health ministry review and

approval steps hard-wired into the data pathway), and apply survey outputs. The net result is streamlined, cost-efficient generation of data of the highest quality that can be rapidly used for programmatic decision-making.

Tropical Data supports baseline, impact and surveillance surveys. It can be deployed quickly and scaled to local need. As the name suggests, Tropical Data intends to open up its service to other diseases in the coming months and years. The goal is to see the control, elimination or eradication of multiple diseases in our lifetime.

For more information, visit our website www.tropicaldata.org

PJ Hooper (International Trachoma Initiative, Task Force for Global Health), **Tom Millar** (Sightsavers), **Lisa A Rotondo** (RTI International) and **Anthony W Solomon** (World Health Organization)

Acknowledgements: Tropical Data has been made possible thanks to assistance from the ENVISION project, led by RTI International and funded by the United States Agency for International Development; the International Trachoma Initiative; The Queen Elizabeth Diamond Jubilee Trust; Sightsavers; the United Kingdom's Department for International Development; and the World Health Organization.



Test your knowledge and understanding

This page is designed to help you test your own understanding of the concepts covered in this issue, and to reflect on what you have learnt. We hope that you will also discuss the questions with your colleagues and other members of the eye care team, perhaps in a journal club. To complete the activities online – and get instant feedback – please visit www.cehjournal.org

1. A postoperative cataract patient should be advised to:	Select one
a Eat a diet low in fibre (roughage)	<input type="checkbox"/>
b Contact the eye clinic in case of worsening sight, increasing pain, redness, swelling or discharge	<input type="checkbox"/>
c Sleep on the operated side	<input type="checkbox"/>
d Resume their regular medication 6 weeks after surgery	<input type="checkbox"/>
2. The following are essential to ensure a good cataract surgical outcome with the minimum of complications:	Select one
a Independent actions by each staff member in the surgical theatre	<input type="checkbox"/>
b Estimation of IOL power by using the refraction of the fellow eye as a guide	<input type="checkbox"/>
c Prophylactic infection control, including the use of povidone iodine	<input type="checkbox"/>
d A stock of 'standard' 21.0D IOLs (to keep costs down)	<input type="checkbox"/>
3. Which of these statements are true?	Select one
a A large drainage bleb may cause localised dryness of the peripheral cornea due to abnormal tear spread	<input type="checkbox"/>
b Before trabeculectomy, a patient should be reassured that their sight is likely to improve	<input type="checkbox"/>
c The intraocular pressure (IOP) on the first day after a trabeculectomy is likely to be the same during follow-up	<input type="checkbox"/>
d Hyphaema after trabeculectomy is almost universal and is not a cause for concern	<input type="checkbox"/>
4. Good quality care of the paediatric cataract patient involves:	Select one
a Telling the parents that they should leave all postoperative care to the professionals	<input type="checkbox"/>
b Monitoring oxygen saturation and pulse rate postoperatively and observing the child for signs of respiratory distress, nausea or vomiting	<input type="checkbox"/>
c Discontinuing follow-up visits 6 weeks after surgery as the long-term incidence of complications is low	<input type="checkbox"/>
d Advising the parents that a child can put in her/his own eye drops after the age of six	<input type="checkbox"/>

ANSWERS

1. b. Patients with these symptoms or signs should contact the eye clinic for advice. Their diet should be high in roughage/fibre to prevent constipation and straining. Patients should not sleep on the operated side and should resume their normal medication immediately.

2. c. Prophylactic infection control is a vital component of preventing complications. The eye team should work together not independently! Estimation of IOL power using biometry will give the best results, rather than using the fellow eye as a guide or keeping just 'standard' IOLs.

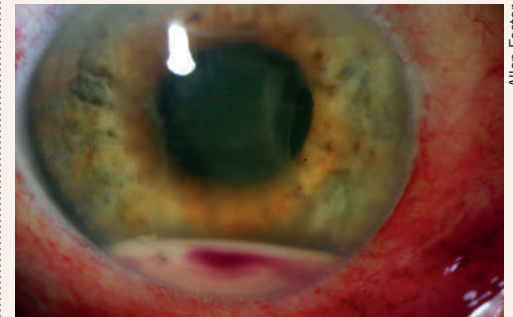
3. a. A large bleb can lift the eyelid off the peripheral cornea causing localised dryness (referred to as 'dellen'). Patients should be counselled that their sight is more likely to stay the same or worsen after trabeculectomy. The IOP on the first day is not a good indicator of the final IOP. Hyphaema is always a cause for concern as it may be associated with a rise in IOP that could further damage the optic nerve.

4. b. The child should always be carefully monitored postoperatively. The parents play an important role postoperatively, supporting the eye team, helping to monitor their child's progress and instilling eye drops. Children should have long-term follow-up because of the high risk of complications, both early and late. Children should not put their own drops in!

REFLECTIVE LEARNING

Visit www.cehjournal.org to complete the online 'Time to reflect' section.

Picture quiz



Allen Foster

A 63-year-old patient presents 3 days after a routine cataract operation with pain and loss of vision in the operated eye; the pain has been increasing over the last 48 hours. The visual acuity in the operated eye is hand movements.

Q1. What three main clinical signs can you see?

Q2. What is the likely diagnosis?

Q3. Which of these statements are true?

- Most postoperative endophthalmitis is caused by fungi
- The most common bacteria which are isolated are gram positive cocci
- Pseudomonas* should be suspected if gram negative bacilli are seen on microscopy
- Bacteria from the patient's own skin may be introduced at surgery
- Fluids introduced into the anterior chamber may be a source of infection

Q4. What treatment would you give the patient?

Q5. Which of the following are useful preventative measures?

- Instill 5% povidone iodine into the conjunctival sac before surgery
- Give prophylactic topical antibiotics after surgery
- Treat any blepharitis or nasolacrimal infection before undertaking surgery
- Use a non-touch technique when operating
- Ensure all fluids used in ocular surgery are sterile

ANSWERS

1. What clinical signs can you see?
 • Red, inflamed conjunctiva
 • Fibrous exudate in the anterior chamber
 • Hypopyon with some blood.

2. What is the likely diagnosis? Postoperative endophthalmitis.

3. b, c, d and e are true. Fungi may cause endophthalmitis but they are not the commonest cause. The commonest causes are gram positive staphylococci or streptococci.

4. What treatment would you give the patient?
 • Consider pars plana vitrectomy (culture the aspirated fluid)
 • Intra-vitreal antibiotics, if possible based upon identification of the responsible organism, e.g. vancomycin, ceftazidime.
 • Systemic antibiotics, if possible based on identification of the responsible organisms.
 • After ensuring the infection is being treated with a suitable anti-microbial, the topical intensive steroids can be given.

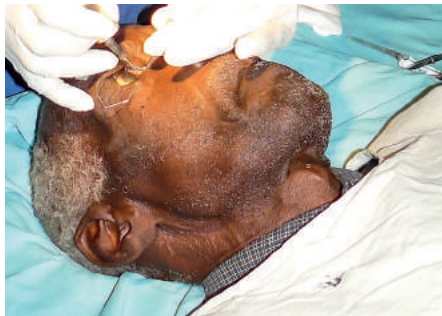5. All the measures listed are useful in preventing endophthalmitis.

Online-only CEHJ issue

Issue 96 of the *Community Eye Health Journal*: Neuro-ophthalmology will be available online at the end of 2016; no paper copies will be distributed.

Visit www.cehjournal.org and subscribe to join our mailing list and receive an email alert when this issue becomes available. Issue 96 can be read online (in HTML format) or can be downloaded as a PDF – free of charge.

Ocular anaesthesia



Tom Eke

Visit www.cehjournal.org/safe-ocular-anaesthesia to read a practical and informative article on **Safe ocular anaesthesia** by UK ophthalmologist Tom Eke. Only available online.

News and notices

New South Asia edition of the *Community Eye Health Journal*

Readers in **Sri Lanka, Bangladesh, Bhutan, the Maldives, Myanmar, Nepal, Pakistan and India** are reminded they will no longer receive paper copies of the International Edition of this journal. Readers are encouraged to subscribe to the new online South Asia Edition by emailing Shivani Mathur at editor@cehjsouthasia.org. Contact Shivani if your educational or training institution requires paper copies.

The International Edition will continue to be available online at www.cehjournal.org and readers can subscribe by emailing web@cehjournal.org

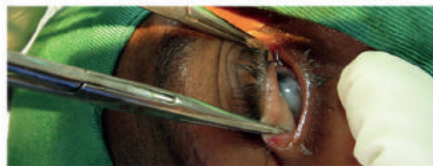
10GA Courses on High-quality surgical care



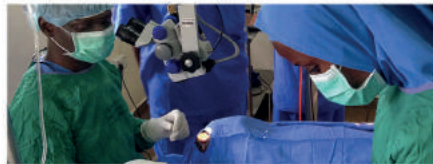The International Agency for the Prevention of Blindness' (IAPB) 10th General Assembly is the premier global event on public health issues related to blindness and visual impairment. Its programme offers courses covering the themes in this issue.

Do visit <http://10ga.iapb.org>

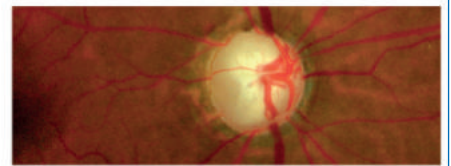
*Come and visit the *Community Eye Health Journal* stand at the 10GA*



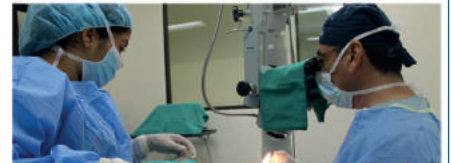Course 7 - Clinical session on recognizing the signs of trachoma



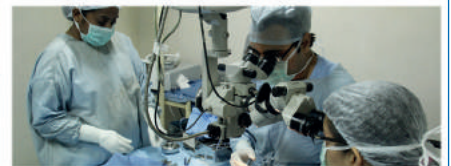Course 11 - Developing high-quality glaucoma care service in Africa



Course 21 - Glaucoma clinical care



Course 26 - How do I scale up my cataract surgical programme?



Course 32 - Quality in cataract surgical training and service



Course 34 - Innovation in eye care

Teaching institutions

German Jordanian University

Email: vtc@gju.edu.jo

University of Cape Town Community Eye Health Institute

www.health.uct.ac.za or email chervon.vanderross@uct.ac.za

Lions Medical Training Centre

Write to the Training Coordinator, Lions Medical Training Centre, Lions SightFirst Eye Hospital, PO Box 66576-00800, Nairobi, Kenya. Tel: +254 20 418 32 39

Kilimanjaro Centre for Community Ophthalmology International

Visit www.kcco.net or contact Genes Mng'anga at genes@kcco.net

Subscriptions

Contact Anita Shah admin@cehjournal.org

Subscribe to our mailing list

Email web@cehjournal.org or visit www.cehjournal.org/subscribe

Visit us online: www.cehjournal.org

www.facebook.com/CEHJournal/

<https://twitter.com/CEHJournal>

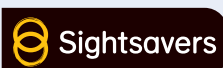Community Eye Health JOURNAL

Supported by:

CONRAD N.



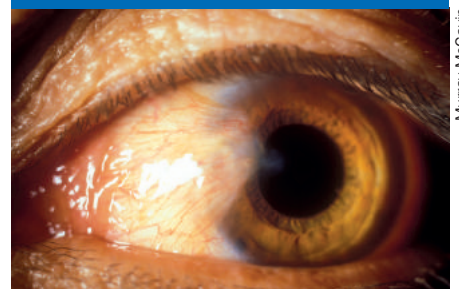
FOUNDATION



The Fred Hollows Foundation



Next issue



Murray McGavin

The next issue of the *Community Eye Health Journal* is about **ocular surface diseases**

Safer ocular anaesthesia



Tom Eke

Consultant Ophthalmologist:
Norfolk & Norwich University
Hospital, UK
tom.eke@nnuh.nhs.uk

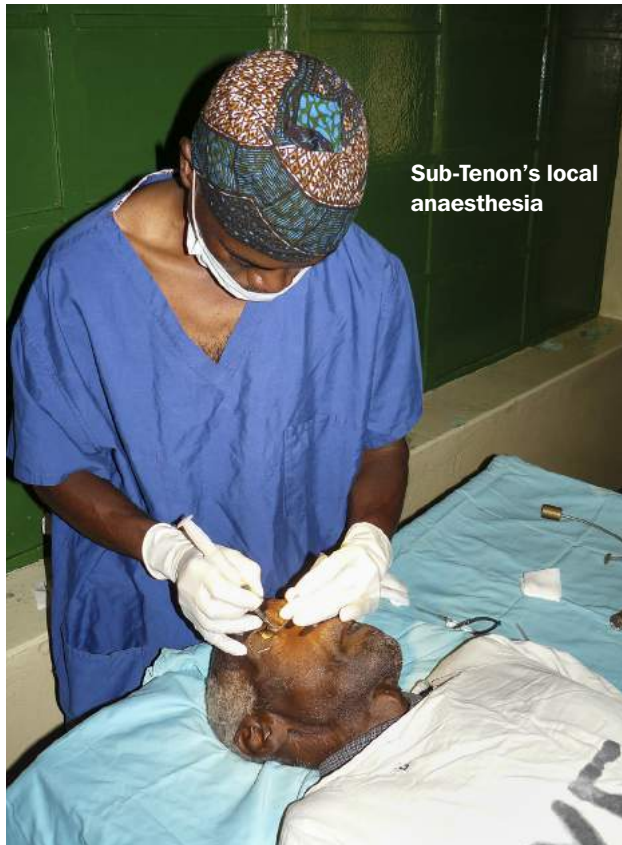Local anaesthesia for eye surgery is usually safe, but serious complications may sometimes occur. Sharp-needle blocks (retrobulbar or peribulbar) can potentially cause blindness or even death. Sub-Tenon's blocks, using a blunt-ended cannula, appear to be much safer. However, they can also cause serious complications.

Sharp-needle techniques (retrobulbar and peribulbar injections)

These appear to have the highest likelihood of serious complications. Blindness may occur if the needle pierces the globe or optic nerve. If the local anaesthetic is inadvertently injected inside the optic nerve sheath, it may track back to the brainstem and cause brainstem anaesthesia. The patient may stop breathing and lose consciousness, and this may be accompanied by fitting (epileptic seizures) and unstable blood pressure. Death is likely to occur if these complications are not managed properly. If the needle pierces an artery, this may cause a tense haematoma (retrobulbar haemorrhage): if not managed properly, this could cause globe ischaemia and blindness. Adrenaline (epinephrine) in the anaesthetic mixture could cause vasospasm, and this has been implicated as a cause for 'wipe-out' syndrome: post-operative blindness with no obvious cause.

Sub-Tenon's

Sub-Tenon's blocks are thought to be much safer than sharp-needle blocks. However, all of the above complications could still occur. If a long metal cannula is used, this might perforate the optic nerve sheath or the arteries at the back of the globe. If these arteries are damaged, blindness appears more likely to occur from ischaemia, rather than due to pressure from a haematoma. The sub-Tenon's technique requires some dissection of the conjunctiva and Tenon's capsule in order to reach the sub-Tenon's space. If there is a lot of scar tissue (e.g. from previous surgery, injury, traditional medicines, etc.) this may result in an



Sub-Tenon's local anaesthesia

W Dean

inadvertent globe perforation. The sub-Tenon's dissection also provides a possible route for bacteria to enter, with the potential for an orbital infection.

Minimal anaesthesia (topical, intra-cameral, sub-conjunctival)

With minimal anaesthesia techniques, these risks are largely avoided, but these techniques have other potential problems. Retrobulbar, peribulbar and sub-Tenon's local anaesthesia will temporarily paralyse the extra-ocular muscles, providing good operating conditions with an immobile eye. By contrast, topical, intra-cameral and sub-conjunctival local anaesthesia result in a potentially 'mobile' eye, and this might lead to challenges for the surgeon and possibly complications and a poor outcome. Many surgeons believe that these techniques are unsuitable for surgery on the 'open eye' (e.g. conventional sutured large incision extra-capsular cataract extraction), because squeezing of the extra-ocular muscles may increase the risk of vitreous loss, choroidal haemorrhage, or a blinding expulsive haemorrhage. These 'minimal' techniques are also usually unsuitable for manual small incision cataract surgery (SICS). Thus, there are many situations in which a 'block' – either a needle block or sub-Tenon's block – is preferable.

Reducing the risks

There are several ways to reduce the risks from local anaesthesia in the eye. Of course, anyone giving local anaesthesia should have appropriate training and an understanding of the relevant anatomy. The anaesthesia/surgical area should be adequately sterile, and there should be sufficient personnel with the right skills for safe local anaesthesia and surgery. There should be an agreed method for monitoring patients during surgery, and an agreed protocol to get help if resuscitation is required.

'Default' local anaesthesia techniques should be chosen, appropriate for your population and the type of surgery you do: for example, pterygium surgery using sub-conjunctival local anaesthesia (given by the surgeon after topical anaesthesia), large-incision cataract surgery using sub-Tenon's block (given 15 minutes before surgery). All patients should be

assessed for problems that could make local anaesthesia more risky or might suggest an alternative technique, e.g. abnormal globe, abnormal globe position and/or conjunctival scarring.

Myopic (near-sighted) eyes are larger and longer than normal, and may also have a posterior staphyloma, which means that local anaesthesia delivered by a needle will be more likely to perforate the globe. Biometry can be helpful, if available: myopic eyes with an axial length over 26 mm have a significantly higher risk of globe perforation from needle blocks using an infero-temporal approach. Before giving the anaesthetic, checks should be done to ensure that the correct patient has the correct operation, on the correct eye. The fornices should be cleaned with povidone iodine 5% to minimise the risk of infection. Aseptic techniques should always be used.

Recommended approaches

Sub-Tenon's block

Sub-Tenon's block provides an excellent balance of risks and benefits for the majority of intraocular surgery.

Disposable sub-Tenon's cannulae are available, although other cannulae can also be used to minimise expense. Many practitioners have had success with plastic intravenous cannulae, metal lacrimal cannulae, or 22-gauge Rycroft cannulae

(e.g the cannulae that are often provided with hydroxypolymethylcellulose [HPMC]). Whichever cannula is used, it is important to avoid pushing the cannula too far back, because of possible damage to the optic nerve or the arteries at the back of the globe (the short posterior ciliary arteries). Of course, if an intravenous cannula is used for sub-Tenon's LA, the sharp needle should be removed first.

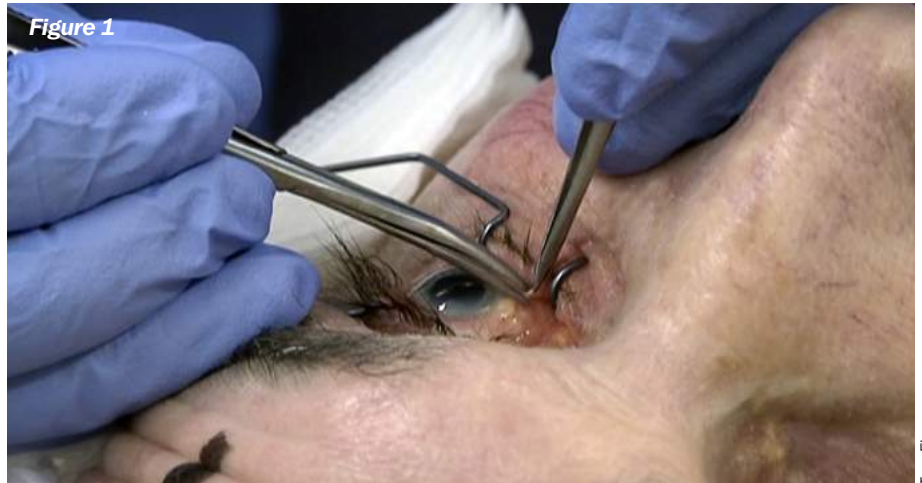Technique for sub-Tenon's LA

A syringe is prepared with anaesthetic and a blunt-ended sub-Tenon's cannula (see previous paragraph). If the surgeon requires anaesthesia without akinesia, 2 ml of lidocaine (lignocaine) will be adequate. If the surgeon requires akinesia, then larger volumes and/or additional hyaluronidase may be used.

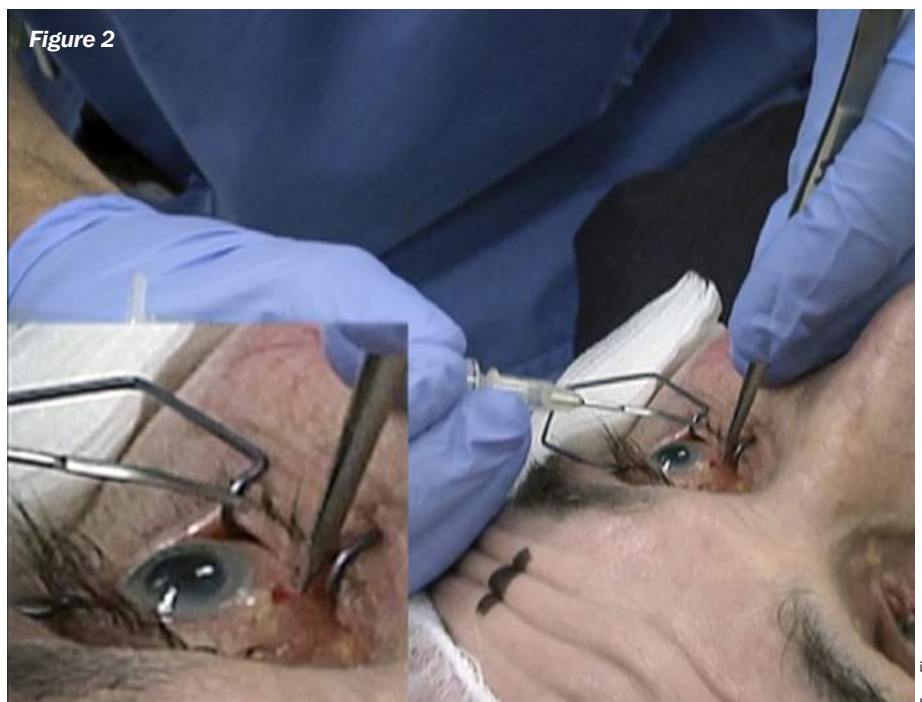- 1 Instil topical anaesthesia (e.g. lidocaine or proxymetacaine) and povidone iodine.
- 2 Insert a lid speculum or hold the eyelids open with the fingers.
- 3 Tell the patient to look 'up and out' (i.e up towards the eyebrows, and out toward the ear on that same side). This will expose the conjunctiva in the infero-nasal part of the globe.
- 4 Grasp the conjunctiva with conjunctival forceps, about 5 mm posterior to the limbus, between the insertions of the medial rectus and inferior rectus (Figure 1).
- 5 Elevate the conjunctiva slightly, and use spring-scissors to make a small 'snip' in the conjunctiva and the underlying Tenon's capsule (Figure 2). When positioned 5–6 mm behind the limbus, a tiny snip (about 2–3 mm) will usually go through both layers at once and expose the shiny white sclera below. If the snip is too small or too superficial to expose the sclera, it may be necessary make another snip to enlarge the hole. Alternatively, it may be necessary to make a small dissection by inserting the closed scissors into the incision, then opening the scissors to spread the tissues. Do this with the scissors positioned perpendicular to the globe, in order to dissect down on to the bare sclera, 5–6 mm from the limbus.
- 6 Hold the posterior edge of the incision with forceps and introduce the sub-Tenon's cannula (Figure 3).
- 7 Advance the cannula posteriorly (tangential to the globe) with a sweeping motion, so that the cannula tip remains in contact with the sclera until it is just behind the equator of the globe. It is usually possible to feel that the cannula tip remains in contact with the smooth sclera as you advance the cannula.
- 8 Slowly inject the anaesthetic and then remove the cannula.

Continues overleaf ➤

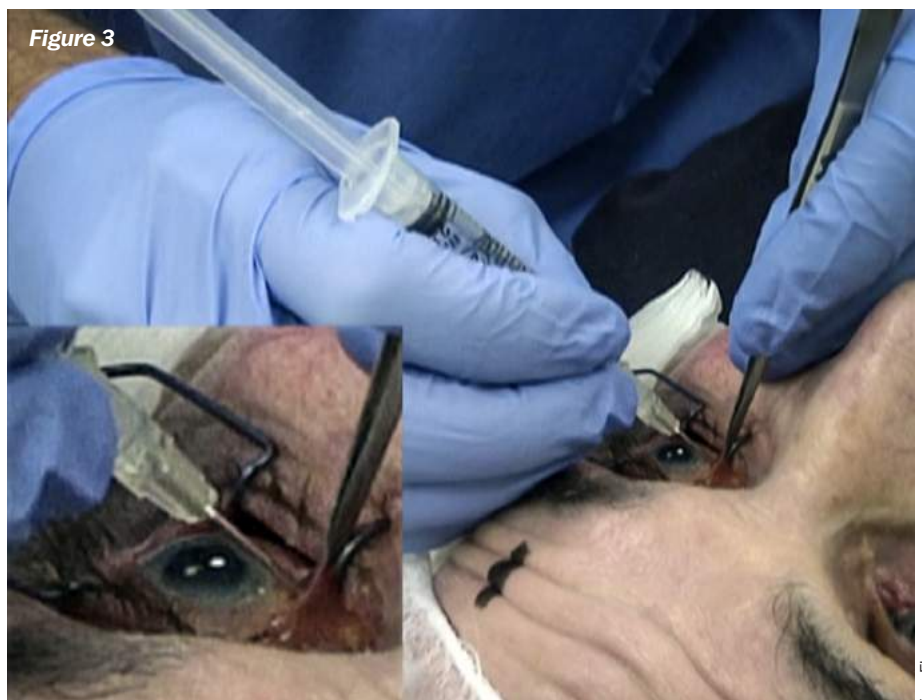Figures 1–3: Sub-Tenon's LA using a 19-gauge 'Stevens' angled metal cannula



Tom Eke

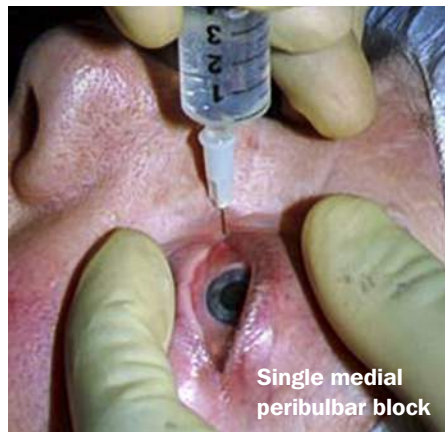


Tom Eke



Tom Eke

- 9 There is usually no need for a pressure device (weight), but it is important to ensure that the lids remain closed so that the cornea does not become dry.



C Kumar

Single medial peribulbar block

If using a sharp-needle technique, the safest approach appears to be the single medial peribulbar block. With this approach, the needle is less likely to perforate the globe or cause a retrobulbar haemorrhage or brainstem anaesthesia, but these complications are still possible with this technique. Instead of the classic infero-temporal approach, the needle is inserted to the medial part of the orbit, through the lacrimal caruncle.

Technique for medial peribulbar block

- 1 Ask the patient to lie on her or his back, facing the ceiling with the eyes in the primary gaze (looking straight ahead)
- 2 Instil local anaesthetic and iodine drops
- 3 Prepare the syringe, using a short needle (e.g. standard hypodermic needle, 25 mm or shorter, narrow gauge, e.g. 25 gauge).
- 4 Position the syringe so that the needle is pointing vertically downward towards the floor. The aim is to insert the needle into the medial part of the orbit, near the medial canthus (where the two lids meet, near the nose).
- 5 Use the needle to pierce the lacrimal caruncle, as far medially as possible. Direct the needle 'backwards' along the medial wall of the orbit, i.e. if the patient is lying down and facing the ceiling, then you should advance the needle towards the floor of the room.
- 6 Inject the anaesthetic slowly, and then withdraw the needle.
- 7 Hold the eyelids closed to prevent corneal drying. Intermittent pressure may aid dispersal of the anaesthetic.

Complications

The surgical/anaesthesia team should be aware of the most serious complications of local anaesthesia and take steps to minimise the risk. It is also important to know what to do, should a serious complication occur.

Brainstem anaesthesia

The signs are variable, but the patient is likely to become drowsy or lose consciousness, within seconds or minutes of the anaesthetic being given. This rare complication is more likely to occur with sharp-needle techniques, but can still occur with sub-Tenon's. Blood pressure may be high, then low, the patient may stop breathing and epileptic seizures may occur. It is important to have a plan for when this occurs: resuscitation should be commenced, and ideally an anaesthetist should be available to manage the airway and monitor the patient in an intensive care setting. With proper support, the patient should recover when the anaesthetic wears off. It is best to try to minimise the risk of brainstem anaesthesia by following the recommendations in this article.

Retrobulbar haemorrhage

This presents with a tense, hard orbit, usually within seconds or minutes of LA being given. Again, this complication is

more likely to occur with sharp-needle techniques. The surgeon should be informed immediately, because the high orbital pressure may cause globe ischaemia and blindness. Making a cut in the lateral canthus (lateral canthotomy) may decompress the orbit sufficiently, with a cut in the skin from the lateral canthus to the lateral bony wall of the orbit. Often it is necessary to make a second cut, at the lateral end of this first cut, directed down toward the infero-temporal corner of the orbital margin (lateral cantholysis). This should allow the orbital pressure to lower, thus saving the sight. The lid can then be repaired after a day or two.

Globe perforation

This can be more difficult to manage. Some cases may resolve spontaneously, but severe scleral lacerations, choroidal haemorrhage, and/or retinal detachment is likely to need vitreoretinal surgery. Patients with globe perforation should be seen by a vitreoretinal surgeon as soon as possible.

Useful resources

For more information on local anaesthesia for eye surgery, numerous resources are available. All of the references and links below are freely available from the internet. The guideline 'Local anaesthesia for ophthalmic surgery' was written with UK practice in mind, but most of the recommendations are applicable worldwide and there is a section on 'Local anaesthesia complications and how to avoid them'. Regular conferences on eye anaesthesia take place in the USA, UK and India, and the World Congress of Ophthalmic Anaesthesia will take place in Indonesia in 2020.

Guidelines

Kumar CM, Eke T, Dodds C, et al. Local anaesthesia for ophthalmic surgery (guideline). London: Royal College of Anaesthetists, Royal College of Ophthalmologists, 2012. <https://www.rcophth.ac.uk/wp-content/uploads/2014/12/2012-SCI-247-Local-Anaesthesia-in-Ophthalmic-Surgery-2012.pdf>

Benjamin L, Allen B, Desai P, et al. Cataract Surgery Guidelines September 2010. London: Royal College of Ophthalmologists, 2010. <https://www.rcophth.ac.uk/wp-content/uploads/2014/12/2010-SCI-069-Cataract-Surgery-Guidelines-2010-SEPTEMBER-2010.pdf>

Practical techniques (all references include illustrations of techniques)

Guise P. Sub-Tenon's anaesthesia. *Local & Regional Anaesthesia* 2012;5: 35-46.

Kumar CM, Dodds C. Ophthalmic regional block. *Ann Acad Med Singapore* 2006; 35:158-167.

Burkat C, Lemke B. Retrobulbar hemorrhage: anterolateral anterior orbitotomy for emergent management. *Arch Ophthalmol* 2005;123:1260-1262 <http://archophth.jamanetwork.com/article.aspx?articleid=417269>

Ballard SR et al. Emergency lateral canthotomy and cantholysis: a simple procedure to preserve vision from sight threatening orbital hemorrhage. *J Spec Operations Med* 2009;9:26-31 www.jsomonline.org/Publications/2009326Ballard.pdf

Websites

British Ophthalmic Anaesthesia Society www.boas.org

Ophthalmic Faculty of the Indian Society of Anaesthesiologists www.ofisa.sankaranethralaya.org

Ophthalmic Anesthesia Society (USA) www.eyeanesthesia.org